

MODERN UPDATE OF OCULAR AND ORBITAL ULTRASOUND

Prof. Dr. med. Mario de La Torre

Dr. Michel Puech

Dr. Peter Good

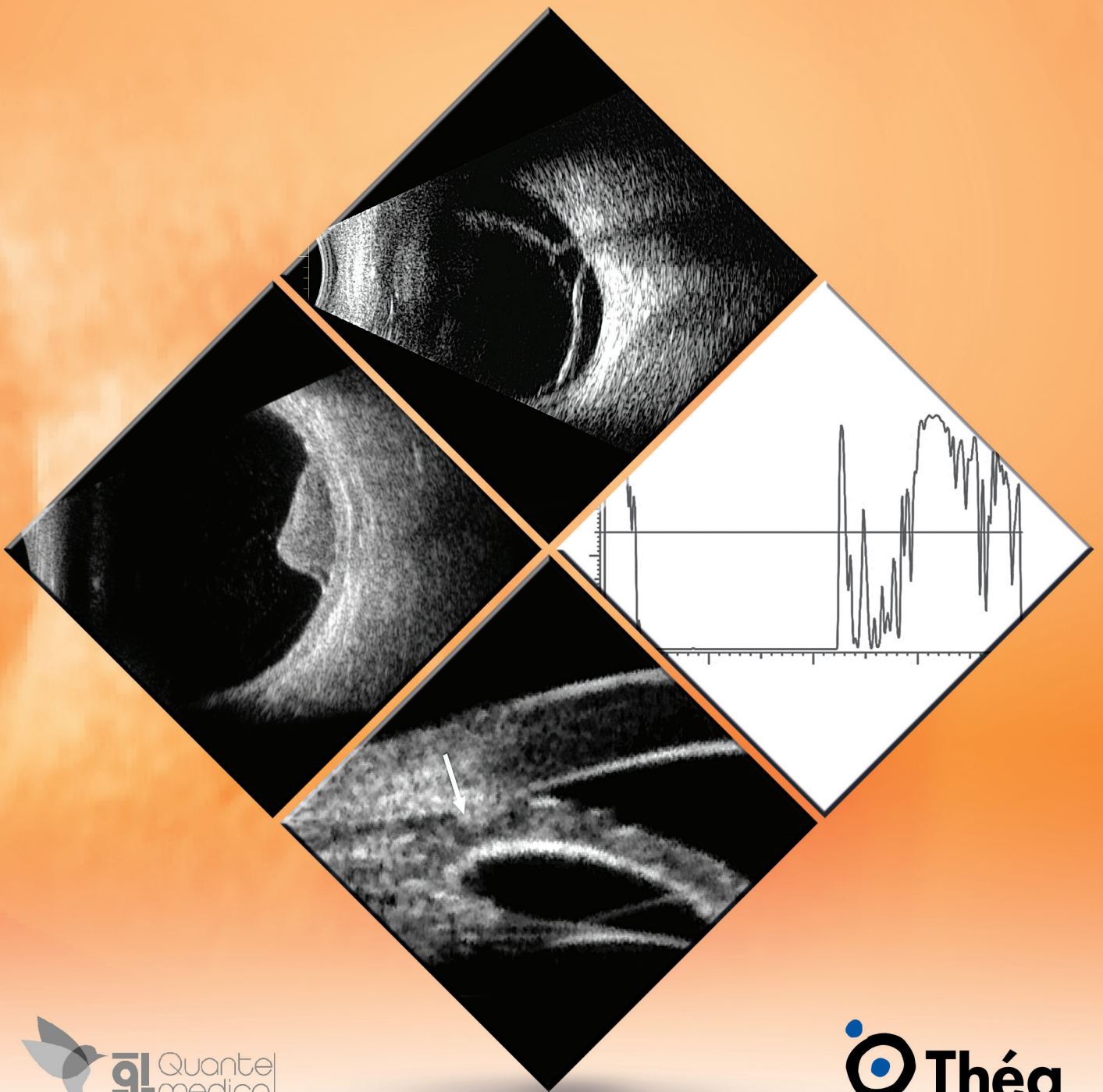

MODERN UPDATE OF OCULAR AND ORBITAL ULTRASOUND

Prof. Dr. med. Mario de La Torre

Dr. Michel Puech

Dr. Peter Good



MODERN UPDATE OF OCULAR AND ORBITAL ULTRASOUND

Prof. Dr. med. Mario de La Torre

Prof. de La Torre is Ophthalmology Professor Qualification, Habilitation and honoured as International Ophthalmologist Education Award by American Academy of Ophthalmology. He is President of Latin-American Council of Ocular Echography, as well as General Secretary Ocular Ultrasound International Society (SIDUO). Professor de La Torre has many international memberships at AAO, COS, SIDUO, Panamerican Ophthalmology Association and Bayern. Medical Regional Association.

Dr. Michel Puech

Michel Puech, MD, MSD Ophthalmologist, Specialized in Ophthalmic Imaging Associate manager of Explore Vision Centers, Paris, France. Manager of VuExplorer Institute (teaching in Ophthalmic Imaging). Inventor and owner of International Patent on High Frequency Ultrasound of Posterior Pole. Author and co-author of many books and articles on ophthalmic Imaging. Member of board of "Société Française d'Ophthalmologie" and past chairman of AIUM Ophthalmology Section (American Institute of Ultrasound in Medicine)

Dr. Peter Good

Dr Peter Good is a Consultant Neurophysiologist at the Birmingham and Midland Eye Hospital heading the UK's largest Ocular Electrophysiology and Ocular Imaging Department. Dr Good has been performing ocular ultrasound for more than 40 years. He is a visiting Professor at Hebei Eye Hospital in China.

EDITION

Edited by:
Laboratoires Théa
12, Rue Louis Bleriot
63 000 Clermont-Ferrand
Tel: +33 4 73 981 436

Work spread with the cooperation of Quantel Medical :
Quantel Medical
11 rue du Bois Joli
63800 COURNON D'AUVERGNE

The content of this book presents the viewpoint of the authors and does not necessarily reflect the opinions of Laboratoires Théa and Quantel Medical.

All rights of translation, adaptation and reproduction by any means are reserved for all countries.

Any reproduction, in whole or part, by any means whatsoever, of the pages published in this book, is prohibited and unlawful and constitutes forgery without the prior written consent of the publisher. The only reproductions allowed are, on the one hand, those strictly reserved for private use and not intended for collective use and, on the other hand, short analyses and quotations justified by the scientific or international nature of the work into which they are incorporated (Law of 11 March 1957, art. 40 and 41, and Penal Code art.425).

PREFACE

In producing this book the 3 authors have combined an instruction on how to perform accurate and reproducible ultrasound images together with an atlas of ultrasound scans. We have including every aspect of ultrasound imaging of the anterior and posterior segment together with orbital images. Whether your interest is angle closure glaucoma, cataract and refractive surgery, vitreo retinal disease, uveal tumours, uveitis or orbital disease there is something for everyone in this book who has an interest in imaging the eye. The authors have more than 100 years of combined International ultrasound experience. Professor de La Torre is from Peru, Dr Puech from France and Dr Good from the UK. They have travelled the world teaching and giving presentations on Ocular Ultrasound.

Ocular ultrasound has a long history. In 1949 Howry and co-workers built the first medical diagnostic ultrasound machine from old American Air Force parts including the running rotating gear from a B29 gun turret! Early ultrasound systems relied on water baths to transmit the ultrasound waves and were restricted to imaging deep cavities and organs. Transducers of 10MHz did not appear until the early 1960s and Mundt and Hughes described the first application of diagnostic ultrasound of the eye in 1956 using a 4 MHz industrial flaw detection system. In 1957 Oksala and Lehtinen were the first to use A scan ultrasound to study a variety of ocular conditions producing a catalogue including retinal detachment, vitreous hemorrhages, foreign bodies and ocular tumours, and were the first to describe ultrasound as a means of measuring the length of the eye. In 1961 Yamamoto et al described an ultrasound Biometry system which used a transducer with a translucent central area to view the retina. Coleman and Carlin were the first to use focussed transducers in 1967. The early ultrasound systems required the use of an oscilloscope screen to view the images. Baum and Greenwood were the first to develop a two dimensional B-scan system in 1959 using a 15 MHz probe. In 1972 Bronson was the first to provide a hand-held B-scan system using a transducer membrane. In 1972

Karl Ossoinig pioneered the use of A-mode ultrasound to provide accurate diagnosis of ocular lesions using a calibrated S shaped amplifier. His Standardized A-scan technique is used to this day and is described in detail in this book. Ossoinig was instrumental in providing the World's first practical diagnostic ophthalmic A and B-mode ultrasound system in collaboration with an Austrian company; the Ketztechnik 7100 MA system. In the following decades ultrasound systems improved enormously particularly in probe development; led by Biovision instruments (BVI) who became Quantel Medical. Increasing probe frequency produces a linear increase in axial resolution but with a linear sacrifice in depth of focus. 50 MHz Ultrabiomicroscopic (UBM) probes to image the anterior segment were not developed until 1990 by Pavlin and Foster. In 1998 Michel Puech showed that the posterior pole can be imaged using high frequency probes up to 50 MHz, with a long focus, opening the pathway to the development of the 20 MHz probe for the posterior pole used in current practice. The phrase "standing on the shoulders of giants" was never more pertinent than in the field of ocular ultrasound.

Modern ultrasound systems incorporate digital LED display screens and highly focussed probes such as the Quantel 20 5A annular probe which allows 20 MHz high resolution images of the whole globe and anterior orbit including giving an image of 5 layers of the retina and is shown in this book. The current development in ultrasound equipment has never been more exciting and it is the hope of the authors to provide an insight into the enormous range of the use of ocular ultrasound in modern ophthalmology. One of the aims of the book is to encourage the every-day use of ocular ultrasound in all ophthalmological specialities. Performing ultrasound and obtaining the kind of images seen in this book is we believe a "magical" experience and the term "you see something new every day" is certainly true in the performance of ocular ultrasound.

We are very grateful for the collaboration between Laboratoires Théa and Quantel Medical in having the foresight to produce an Ophthalmic Ultrasound book available to all. We hope you enjoy reading this book as much as we have enjoyed writing it.

Mario, Michel and Peter

I want to thank my family that has always been with me, in the adventure of continuing learning and teaching. Also my special thanks to my teachers: Gerhard Hasenfratz and Wolfgang Haigis, as well as Karl Ossoinig who introduced me to the fascinating world of ultrasound

Mario de La Torre

*To my father for inspiring me to become a scientist.
To my friends and colleagues of SIDUO for providing continuous support and wonderful international ultrasound events.
To Professor James Crews who was my mentor and supported me in developing the ultrasound service in 1974.*

Peter Good

*In the mid 80's, I was an ophthalmologist in training at Hotel Dieu de Paris, France, and my head of department, Pr Yves Pouliquen, asked me to use this very uncommon device performing ultrasound for the eye (Ophtascan, Quantel Medical). I have learn basis of ultrasound with Olivier Berges at Rothschild Fondation, and Dan Reinstein, Ron Silveman and Jackson Coleman have given to me the chance to work with Artemis (Very High frequency anterior segment ultrasound arc scanner). I have to thank all these mentors for this critical input in my professional life by pushing me to ophthalmic imaging field with now all my time devoted to this fascinating domain with my Explore Vision Team.
Thanks also to my family for all this long and very powerful support.*

Michel Puech

TABLE OF CONTENTS

01 - B-MODE BIOMETRY

Introduction	20
B-mode measurement techniques	20
Errors to avoid	24
Advantages of B-mode biometry	28
Special cases	40
Conclusion	42

02 - METHODOLOGY OF STANDARDIZED ECHOGRAPHY

Introduction	46
Examination techniques	52
Eye and orbit basic examination	60
Position of the patient and the device	62
Basic techniques: A and B-mode	64
A-mode	64
B-mode basic examination positions	64
Trans and paraocular scanning	66
B-mode types of sections	68
Special techniques	71
Topographic echography	72
Size or borders	74
Quantitative echography	76
Quantitative ultrasound type I	78
Quantitative ultrasound type II	80
Kinetic echography	82
Consistency	84
A and B-mode image	86

03 - VITRORETINAL & ORBIT

The normal globe	90
The normal vitreous	94
Vitreous hemorrhage	98
Vitreous cells	104
Retinal tears and holes	108
Retinal/choroidal detachments	116
Trauma	126
Optic disc anomalies	130
Retinal and choroidal lesions	140
Inflammation and scleritis	146
Orbital pathology	152

04 - THE BENEFITS OF ULTRASOUND BIOMICROSCOPY (UBM)

UBM technique and examination	160
Angle opening distance (AOD) analysis	160
UBM analysis of angle closure mechanisms	162
Open angle analysis	166
Post-treatment analysis	168
UBM and tumours	170
UBM and implants	172
UBM and trauma	174
UBM and the retinal periphery	174
Conclusion	174

In recent years there have been major advances in ocular imaging particularly in the field of ocular coherence tomography (OCT) and in the last few years we have seen developments such as Angio OCT and steady state OCT, and there are many advances in wave front imaging particularly of the anterior segment. However, there remains an imaging modality which has been steadily developing and often forgotten, but which does not rely on optical technology. Ultrasound imaging utilises technology that can image any part of the eye under any circumstances.

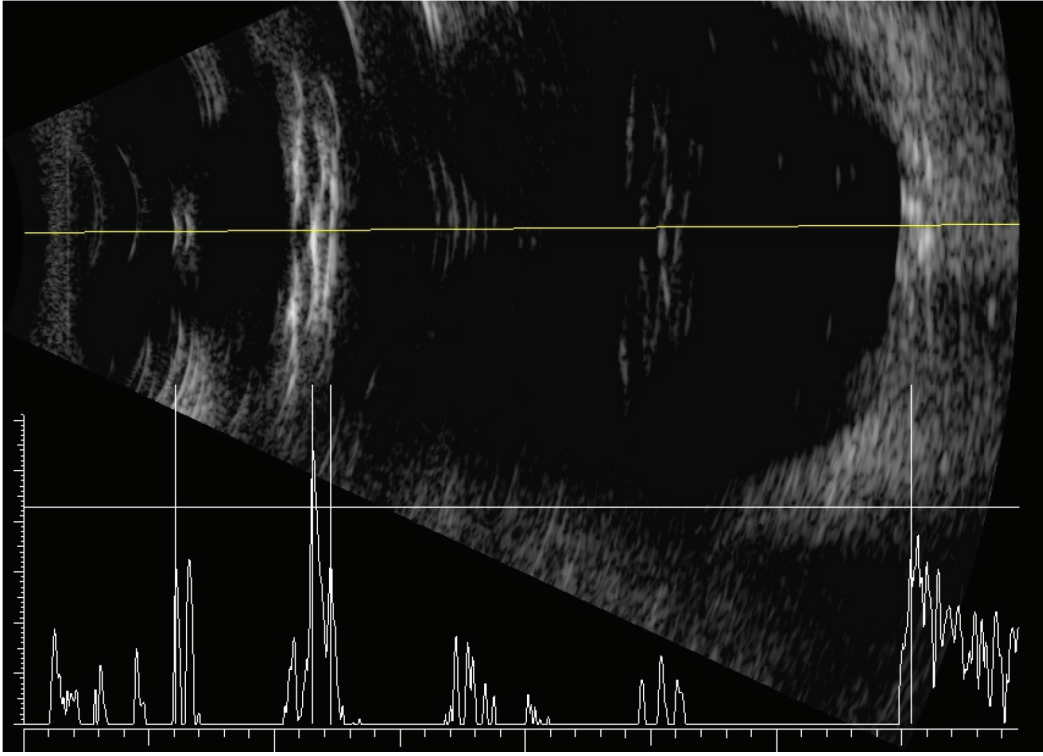
The use of ultrasound in ophtalmology dates back more than 50 years with the use of the first practical ultrasound machine; the Kretz A-scanner, which was basically an oscilloscope and a transducer that measured reflectivity from different ocular structures. This basic technology is still used today and forms the basis of the **Standardized A-scan**. The first practical **B-scan ultrasound** machine was not available until the late 1970's and had very poor resolution. Early ultrasound machines utilised analogue technology which eventually achieved high resolution until the turn of the century when it was replaced by digital ultrasound. In the last decade ultrasound imaging has developed enormously with improved ultrasound probes in particular; improvements in axial and lateral resolution utilising higher frequency probes at 20 MHz frequency for the posterior segment and 50 MHz for the anterior segment. Greater depth of imaging has also been achieved with improved focussing. The latest development is the annular 20 MHz probe developed by Quantel Medical which allows high resolution imaging of the whole globe and orbit.

Ultrasound technology still relies on the use of vibrating piezo electro crystals which are modified by reflected ultrasound waves from ocular structures giving variation in reflectivity and sound attenuation which is then amplified and converted into a **B-scan** by combining the **A-scans** into a 50 to 60 degree array, modified by

display brightness, the dynamics of the amplifier and screen resolution. The B-scan (B stands for brightness) is made up of an array of A-scans. The B-scan probes vary between 10 and 20 MHz frequency. The relationship between axial resolution and frequency is linear as is the relationship between frequency and depth which is an inverse linear relationship, but which can be modified by focussing the transducer and using annular probe technology.

The principal use of ultrasound is in opaque media in order to identify retinal detachment, vitreous hemorrhage, choroidal detachment, inflammatory disease, endophthalmitis and retinal tears etc. This is the main use of the 10 or 15 MHz probe. These probes can also be used in cases of trauma to identify foreign bodies and scleral rupture. They can also evaluate orbital pathology including orbital tumours and pseudo-tumours, thyroid eye disease and optic nerve structural abnormality as well as other extraocular muscle abnormalities. As well as the A-scan probe the B-probe can be used in making accurate biometric measurements. Additionally, 20 MHz probes can be utilised to evaluate and diagnose uveal tumours, posterior scleritis, optic disc abnormalities and anterior orbital pathology as well as identifying macular pathology. The 50 MHz probe is used to evaluate anterior segment pathology, particularly angle closure glaucoma, but also Iris and ciliary body tumours and cysts. It is also useful in evaluating lens abnormalities and IOL complications such as capsular distension syndrome. A-scan probes are used mainly in biometric measurement of the eye, but the standardized A-probe is a calibrated probe which can be used to evaluate structural changes in uveal tumours.

This book is an atlas of ocular ultrasound which reveals to the reader the enormous variation in the use of ocular ultrasound, beyond its use in opaque media. Ultrasound is a unique imaging tool which can look at internal as well as external structure of the eye and orbit and which can evaluate ocular pathology from the cornea to deep into the orbit.



01

B – MODE BIOMETRY

INTRODUCTION

B-mode biometry is a method for measuring the axial length of the globe. The measurement is based on A-mode ultrasound guided by a B-mode horizontal axial scan.

This B-mode axial length measurement has no limitation in case of cloudy media. Furthermore, posterior pole B-mode ultrasound examination can be performed during biometry for vitreoretinal analysis prior to surgery.

I. B-MODE MEASUREMENT TECHNIQUES

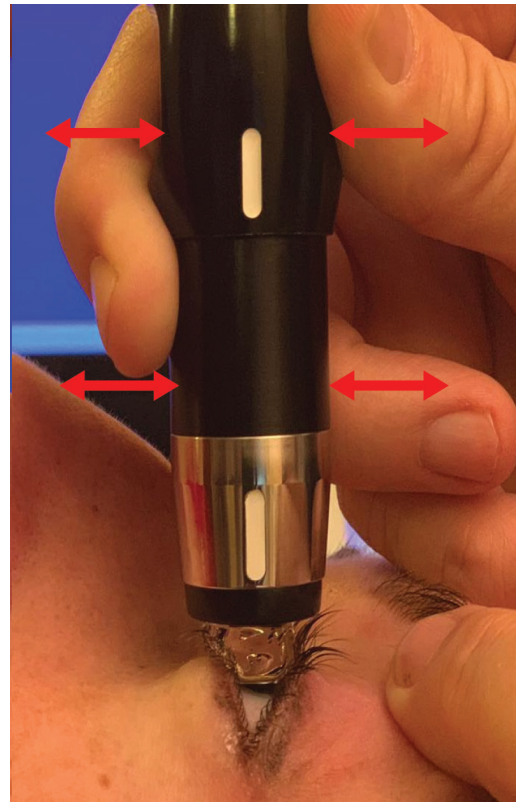
B-mode biometry is performed with the patient in supine position, eyelids open, usually without local anaesthetic (in this case, pupil dilation is not necessary). A target point on the ceiling helps patient keep a steady gaze, using contralateral eye.

The B-probe is brought in front of the eye using a coupling ophthalmic gel applied to the tip of the probe. This “pseudo-immersion” technique avoids corneal indentation and does not require a scleral shell, which can be tricky to handle. (Fig 1)

The probe is held vertically in front of the corneal apex, with the marker on the probe positioned to the right or left in order to obtain a horizontal scan. A gentle up and down translation of the probe is used to highlight interfaces on the screen showing a horizontal scan through the visual axis (Fig 2). At this stage, it is important not to tilt the probe in any axes.



*Fig 1: B-mode biometry technique:
The B-probe is prepared with a small quantity
of ophthalmic gel.*



*Fig 2: The B-mode probe is positioned with
a gentle contact of the gel in front of the
corneal apex in a perpendicular way. Just by
applying an horizontal translation of the probe
we can unlight the interfaces on the screen
avoiding all other inclination of the probe.*

On the screen, the horizontal axial scan is obtained by aligning the anterior and posterior corneal interfaces, the anterior and posterior lens interfaces, and the optic nerve head, which can be used to identify the macular region. (Fig 3)

When the cornea and the lens interfaces are aligned with a highest reflective response, the optic nerve head is very often observed at the fundus.

A control vector is superimposed over this horizontal axial scan to identify the measurement axis along the visual axis. The visual axis forms a 10 to 15° angle temporally to the optic disc. (Fig 4)

Interfaces can be shown on A-mode (Amplitude mode) in a direct correlation with B-mode (Brightness mode) scan. When displayed together, there is a spatial correspondence between the brightest images in B-mode and the highest peaks in A-mode (Fig 4). Callipers can then be added to mark off the sections of the globe through which ultrasound beam is conducted with a different ultrasound speed (Fig 5). Ultrasound devices do not measure distances directly: they measure the travel time of the ultrasound beam. This travel time is converted into a distance based on the ultrasound speed into the anterior chamber (1532 m/s), into the lens (1641 m/s) and the vitreous (1532 m/s).

To ensure reliability of B-mode axial length measurement, it is recommended to perform a series of four or five measurements selecting the values that fall within +/- 0.1 mm.

Optical biometry performed by a trained operator can be used very effectively to demonstrate the reliability of B-mode biometry results. It is very useful to calibrate B-mode biometry technique when axial length measurement is known by optical biometer. This learning curve will lead to a very high efficacy of B-mode biometry in case of cloudy media with no optical biometry available.

An automatic keratometer should be used for keratometry (in millimeter) and IOL calculation, using the ultrasound device calculator.

When pseudo-immersion axial length B-mode measurement and automatic keratometry are combined, the ULIB website's optimised A-constant can be used for the SRK/T formula. Note that nominal A-constant column corresponds to measurements taken using a contact A-scan.

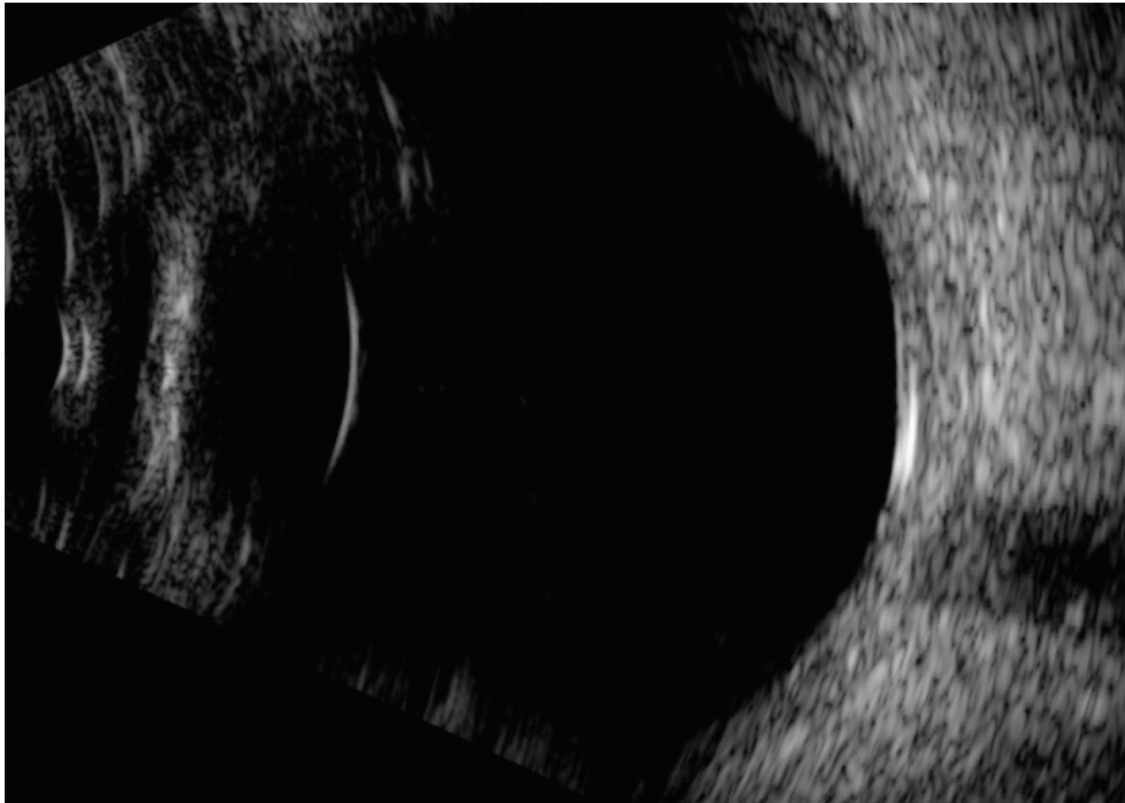


Fig 3: Horizontal axial scan with double corneal arc, double lens arc aligned and optic nerve head visualisation. This scan shows perpendicularity of ultrasound beam against interfaces : optic nerve head visualisation allows to define macular region positioning.

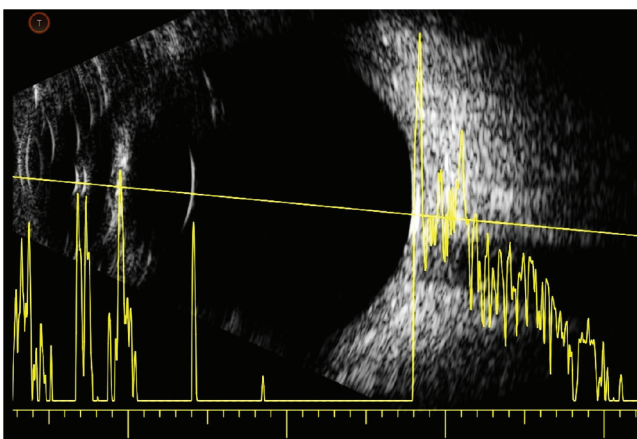


Fig 4: Horizontal axial scan with control vector: The higher interface reflectivity with B-mode gives the higher peak with A-mode with a direct spacial relationship.

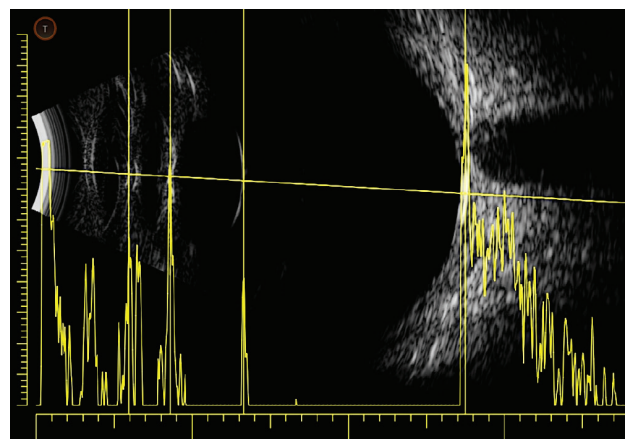


Fig 5: Calliper positioning selecting intra-ocular segment with various ultrasound speed : Cornea and ACD: 1532m/s, Lens: 1641m/s, Vitreous : 1532 m/s.

ERRORS TO AVOID

Wrong calliper positioning can lead to axial length measurement error (Fig 6), with axial length shortening when the lens section is measured as shorter than it actually is, and *vice versa*. This is a key point of B-mode biometry, since it helps to clearly identify the posterior lens capsule. It should be noted that A-mode biometry—generally performed in automatic mode—automatically selects the highest peak as the posterior lens capsule, which can lead to wrong measurement in case of lens opacities.

B-mode biometry measurements are taken with the eyelids open, since this makes it easier to distinguish the front of the cornea. When measurements are taken with the eyelids closed, it is not always possible to precisely identify the anterior cornea, and the patient cannot be instructed to look in a specific direction. (Fig 7)

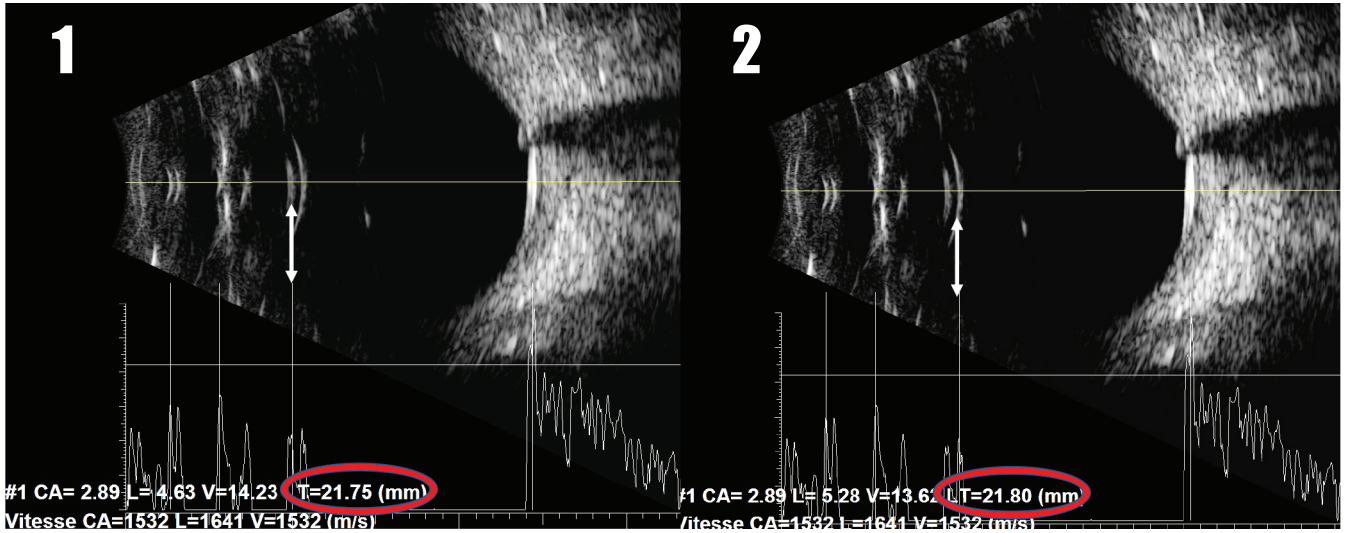


Fig 6.1: Posterior lens calliper positioning on the first A peak with intra lens opacities gives an axial length of 21,75mm.

Fig 6.2: Posterior lens calliper positioning on posterior lens capsule gives an axial length measurement of 21,80 mm wich is the real value.

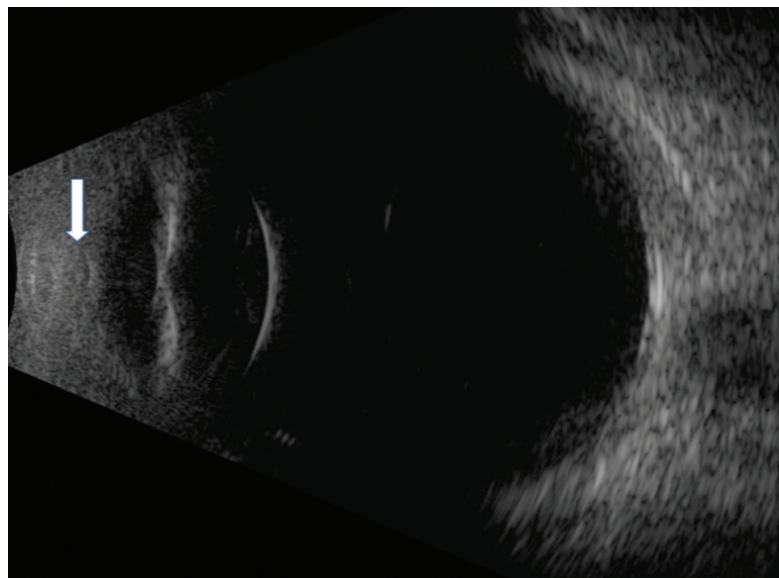


Fig 7: B-Mode biometry with closed lids: Anterior corneal surface is hardly distinguished against lid tissue.

The axial length measurement have to use 4 callipers designed to select the various segments into the globe with various ultrasound speed. Using the only two callipers, designed for tissue lesions, with a 1550m/s ultrasound speed can lead to axial length measurement error. (Fig 8)

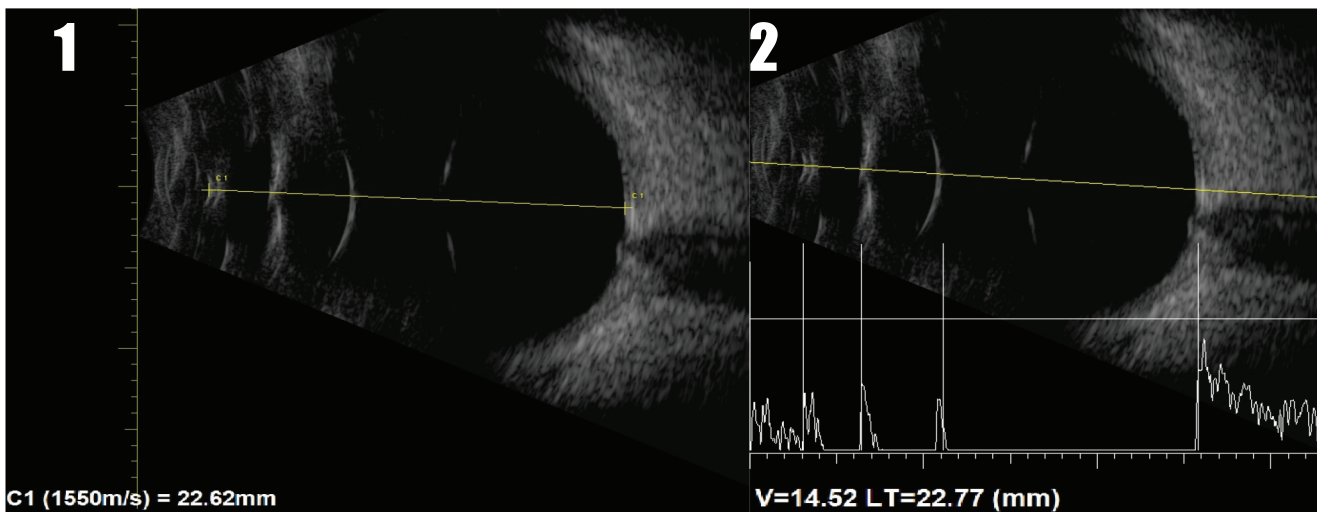


Fig 8.1: Axial length measurement of 22,62mm with 2 callipers for tissue measurement: Ultrasound speed is 1550 m/s between the 2 callipers with an axial length measurement error.

Fig 8.2: By using 4 callipers separating ultrasound speed in each intra-ocular segment, axial length measurement is more precise (22,77mm).

ADVANTAGES OF B-MODE BIOMETRY

B-mode biometry is a very useful alternative for axial length measurement when optical biometry is impossible in case of cloudy media (between 3 and 7% non-response, based on the literature).

B-mode biometry can measure axial length regardless of the cause of media opacities: cataracts, large floaters, vitreous hemorrhage or retinal detachment. (Fig 9)

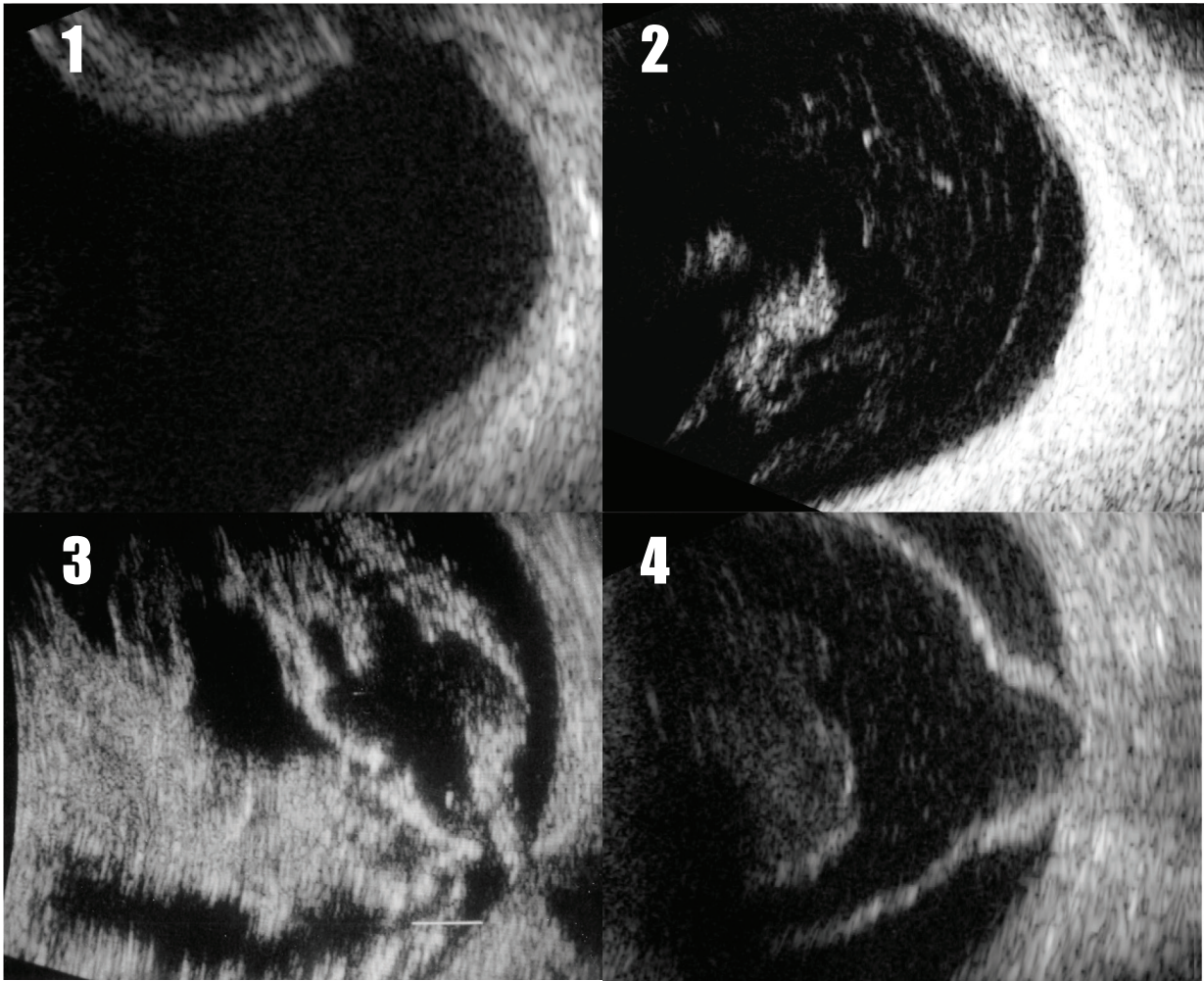


Fig 9.1: Dense cataract with B mode ultrasound imaging of periphery.

Fig 9.2: Advanced posterior vitreous detachment with dense floater on visual axis.

Fig 9.3: Dense intra vitreous hemorrhage.

Fig 9.4: Retinal detachment attached to optic nerve head.

The presence of numerous intravitreal echoes due to asteroid hyalosis does not prevent axial length measurement in B-mode, whereas it can sometimes be more difficult to recognise the retina interface with A-mode. (Fig 10)

The presence of air or gas in the vitreous cavity can prevent ultrasound measurement, since this blocks the ultrasound beam.

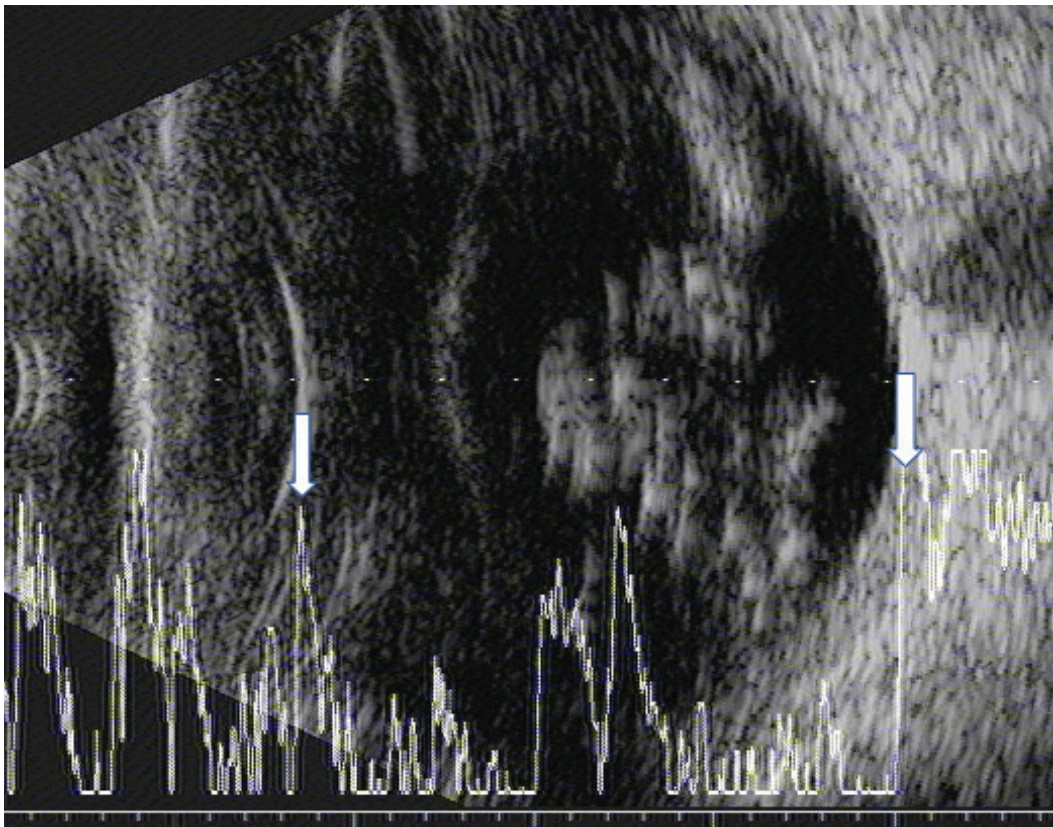


Fig 10: In case of dense asteroid hyalosis with many intra-vitreous echos, B-mode scan helps to identify posterior lens peak and retinal peak.

The ability to obtain a horizontal axial scan provides an overview of the general shape of the eyeball: short or long, with various features of myopic staphyloma, located either temporally or nasally to the optic disc. (Fig 11)

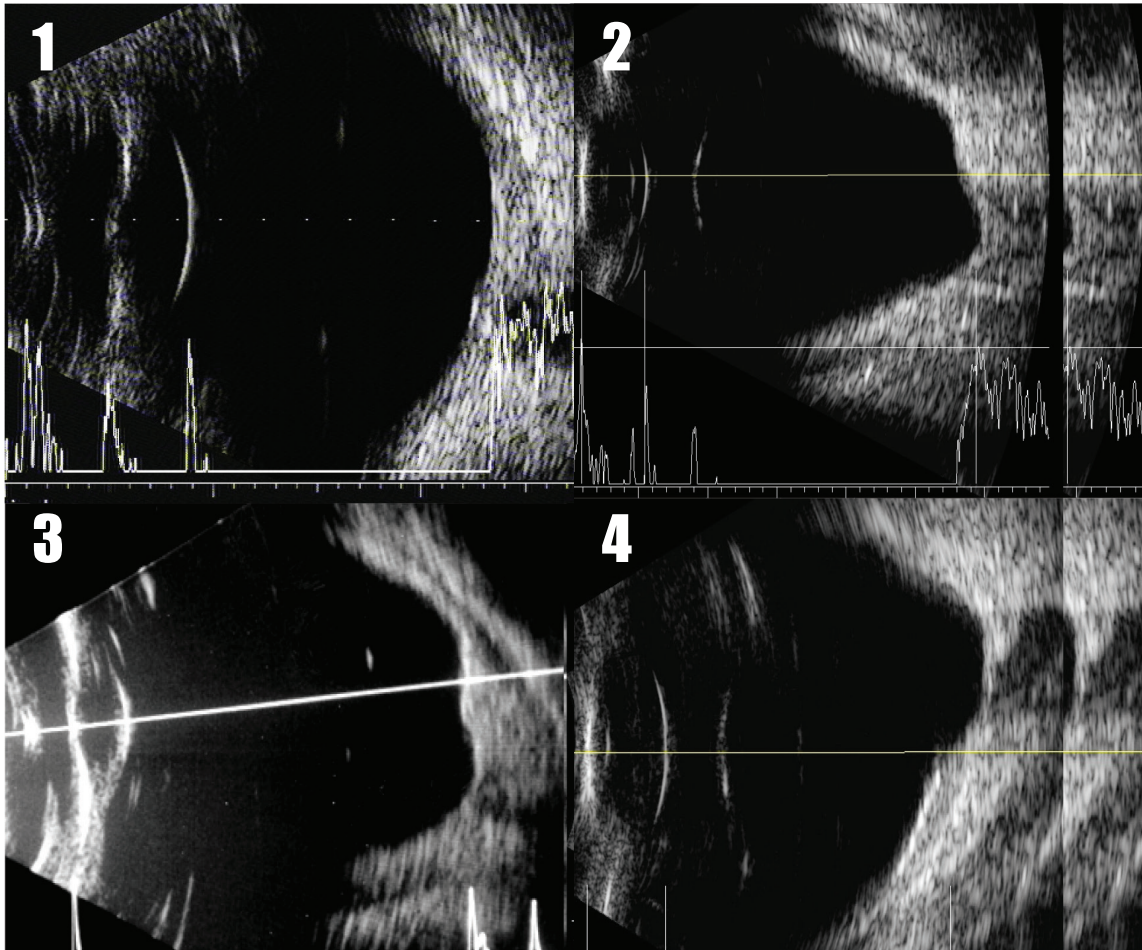


Fig 11.1: Short eye with a smooth curve of the wall and a short vitreous segment.

Fig 11.2: In case of myopic staphyloma the axial length measurement has to be taken in temporal of optic nerve head instead of the end of staphyloma.

Fig 11.3: Myopic staphyloma with dome shape macula.

Fig 11.4: Myopic staphyloma with oblique posterior pole with regard to visual axis.

A 20 MHz posterior pole examination can be performed in addition to B-mode biometry in order to better analyse wall abnormalities. This very high resolution scan of the macular region, can reveal wall thickening with an epiretinal membrane, macular hole or age-related macular degeneration. (Fig 12)

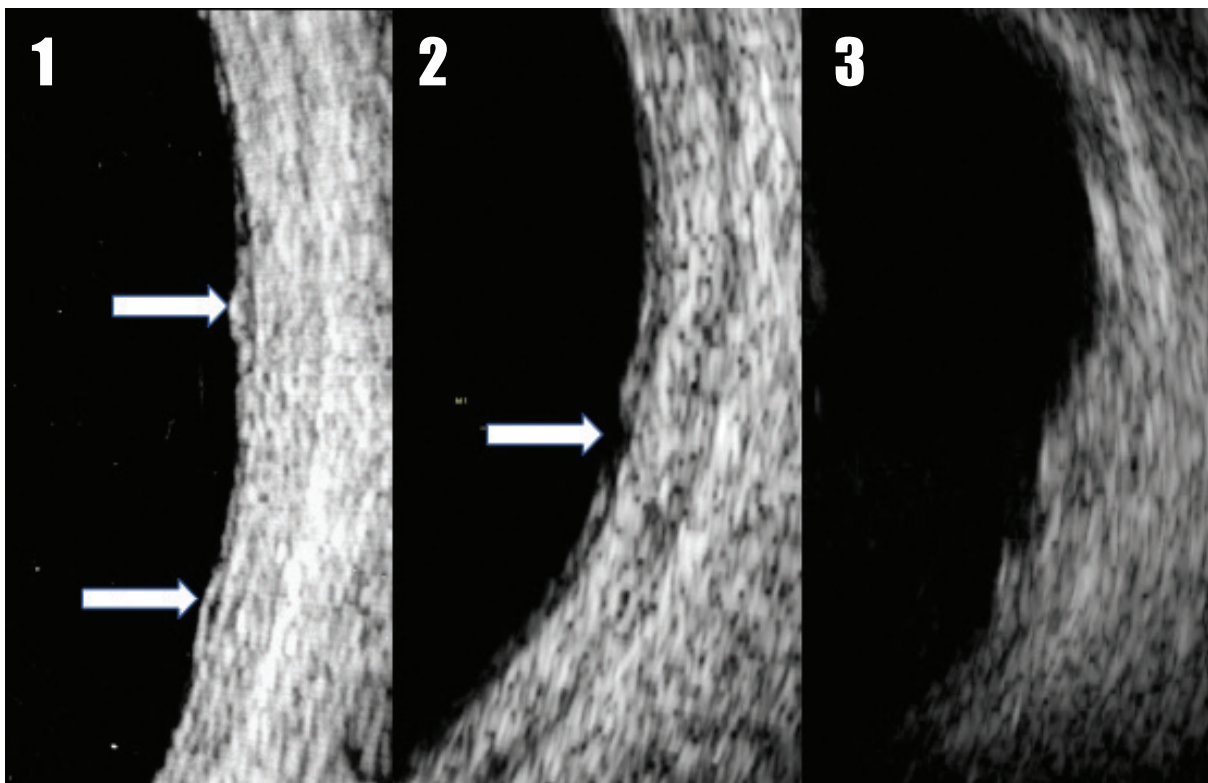


Fig 12.1: Epiretinal membrane better seen with 20 MHz probe.

Fig 12.2: Macular hole.

Fig 12.3: Age-related macular degeneration.

The optic nerve head analysis, can diagnose optic disc excavation or drusen. (Fig 13)

B-mode ultrasound examination can also provide a full assessment of the vitreoretinal interface, revealing the presence or absence of posterior vitreous detachment or retinoschisis and, in some cases, peripheral complications such as horseshoe tears or retinal detachment. (Fig 14)

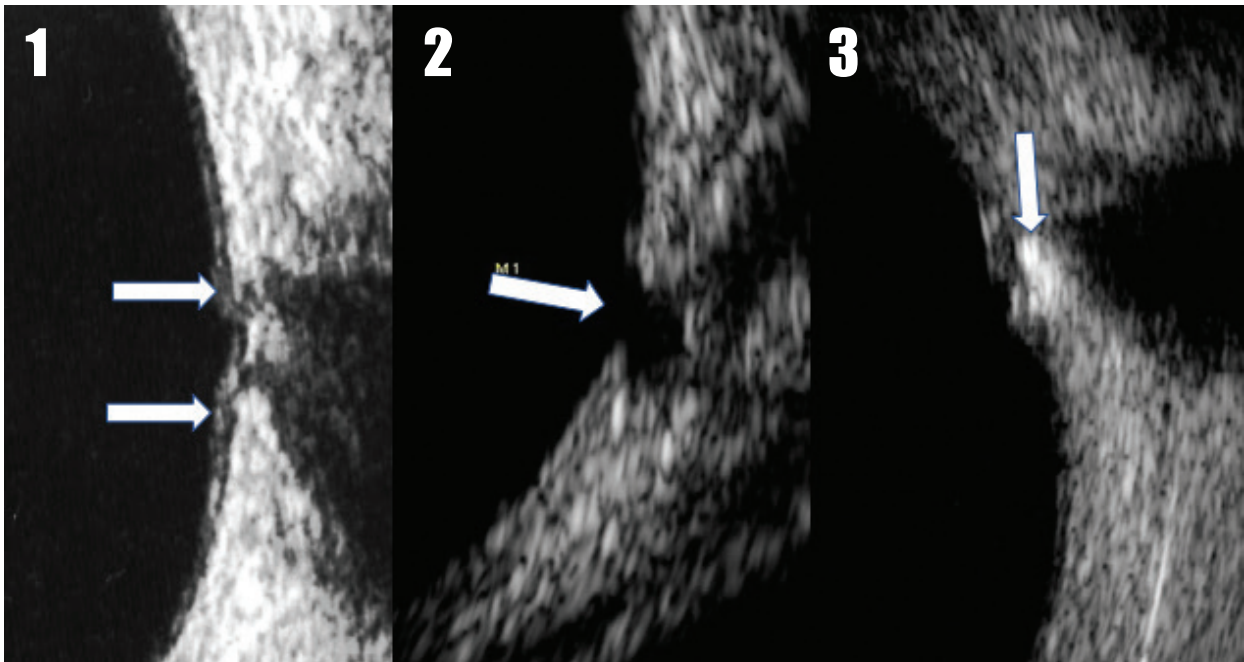


Fig 13.1: Normal optic nerve head with visualization of optic fibers (20MHz Probe).

Fig 13.2: Advanced glaucoma with large optic nerve head excavation.

Fig 13.3: No optic nerve head excavation due to optic nerve head drusen.

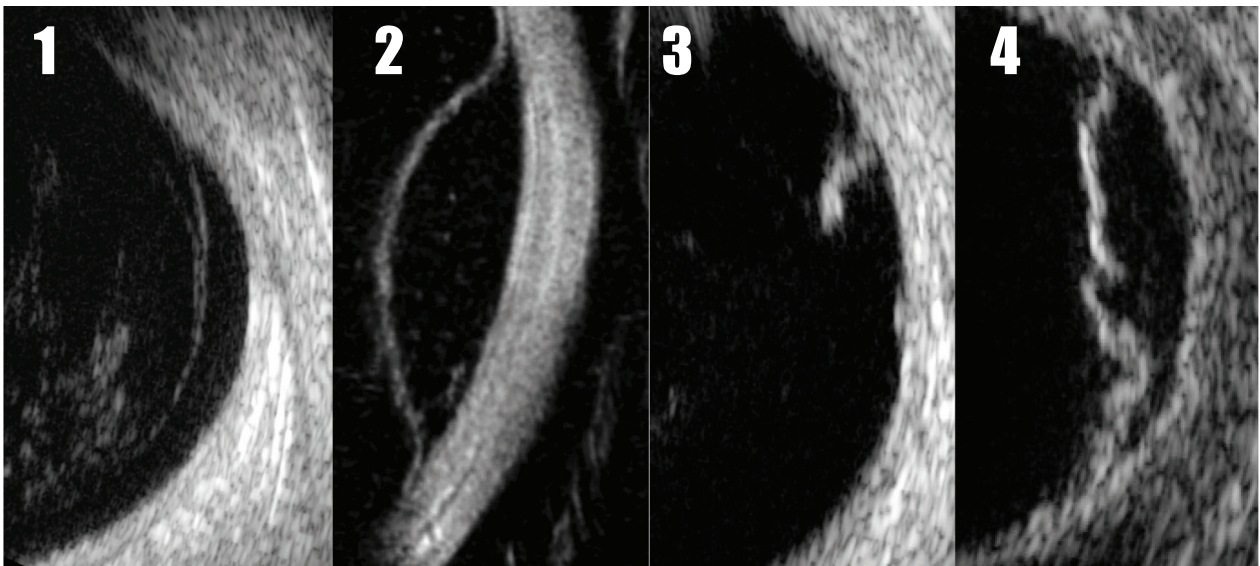


Fig 14.1: Posterior vitreous detachment without retinal side effect.

Fig 14.2: Retinoschisis with a 20 MHz probe.

Fig 14.3: Retinal tear.

Fig 14.4: Corrugated membrane characteristic of retinal detachment.

Wall thickenings such as naevi or tumours may be diagnose during B-mode biometry differentiating a mild echogenic or hyperechogenic naevus from a hypoechogenic melanoma with choroidal excavation.

(Fig 15)

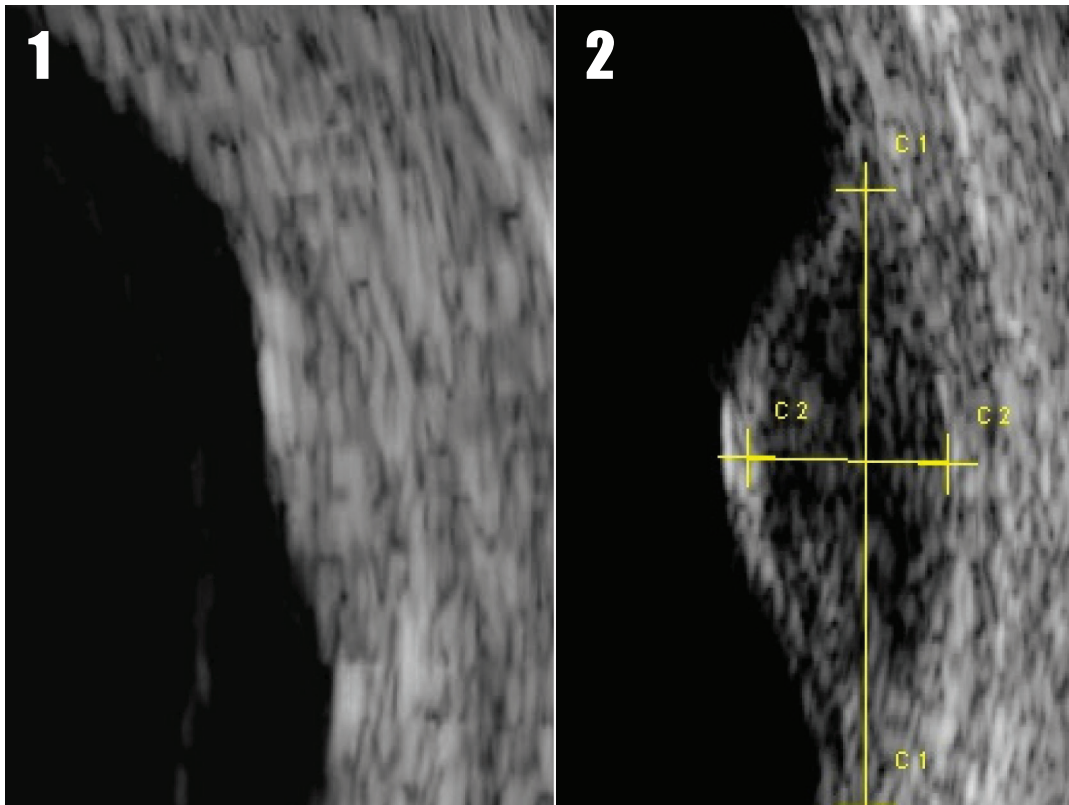


Fig 15.1: Wall thickening with mean echogenic tissue of choroidal naevus.
Fig 15.2: Hypoechoic thickening of the wall with choroidal excavation in case of choroidal melanoma.

SPECIAL CASES

Intraocular implants

B-mode biometry can be performed on a pseudophakic eye by positioning the lens callipers on the front and back of an acrylic IOL (Fig 16). For PMMA or silicon IOL ultrasound speed has to be adjusted in the ultrasound device settings.

For phakic IOL, the measurement can be taken by positioning the anterior calliper on the front of the phakic IOL and the posterior calliper on the posterior lens capsule. (Fig 17)

Silicone oil-filled eyes

The axial length of silicone oil-filled eyes can be measured by adjusting the ultrasound speed for the section of the vitreous filled with silicone oil (986 m/s) in the device settings. Do not forget to reset the device to normal vitreous speed for the next patient measurement.

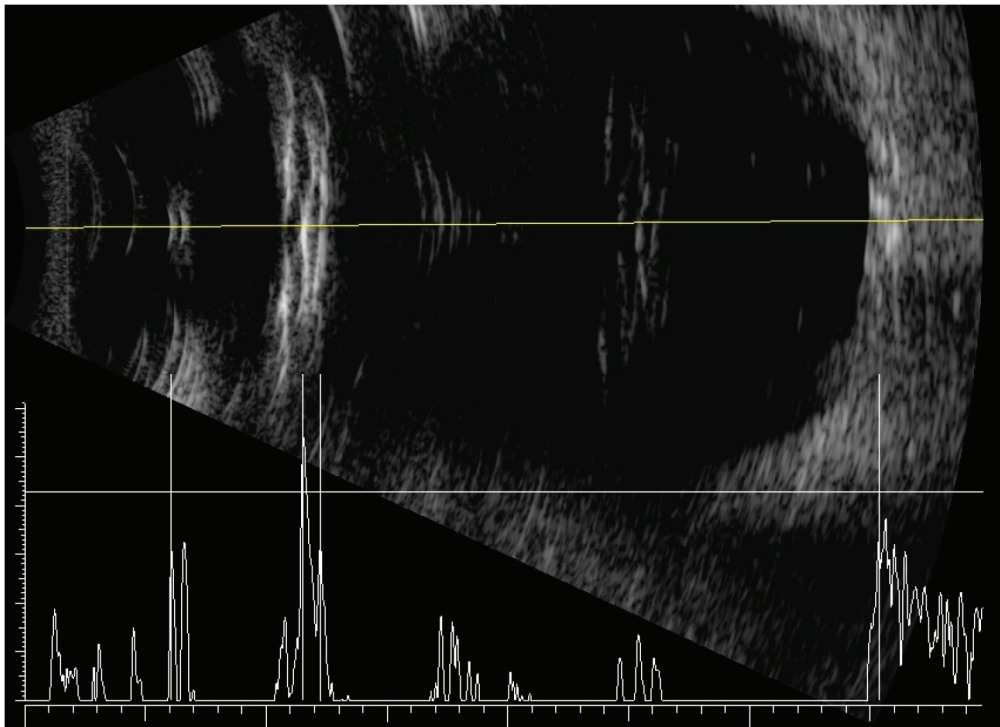


Fig 16: B-mode biometry in case of pseudophakic eye : calliper positioning on anterior and posterior IOL interfaces.

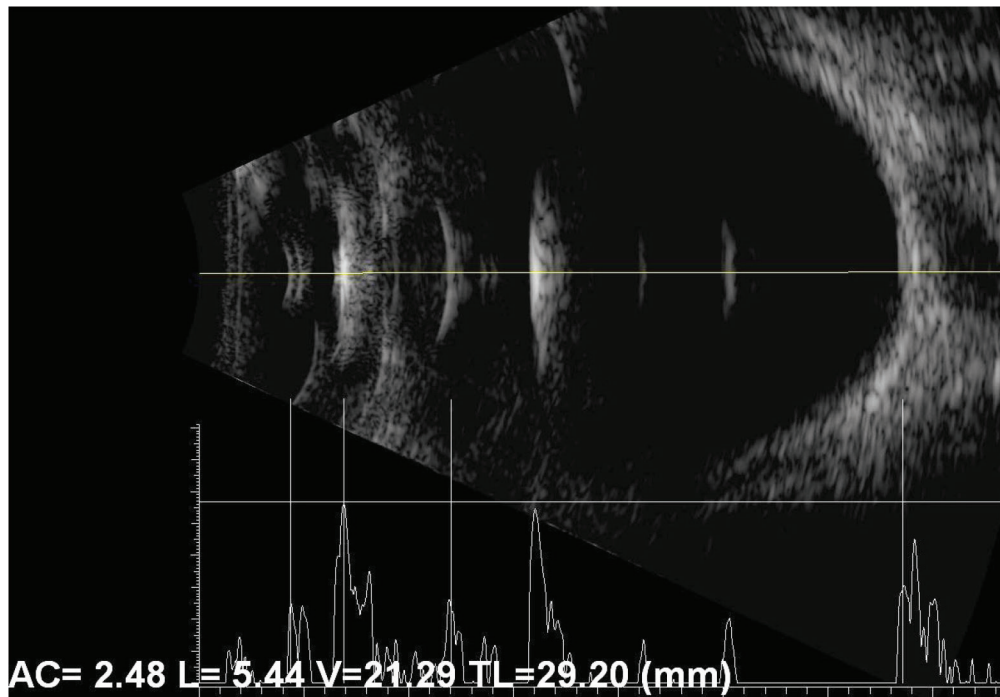


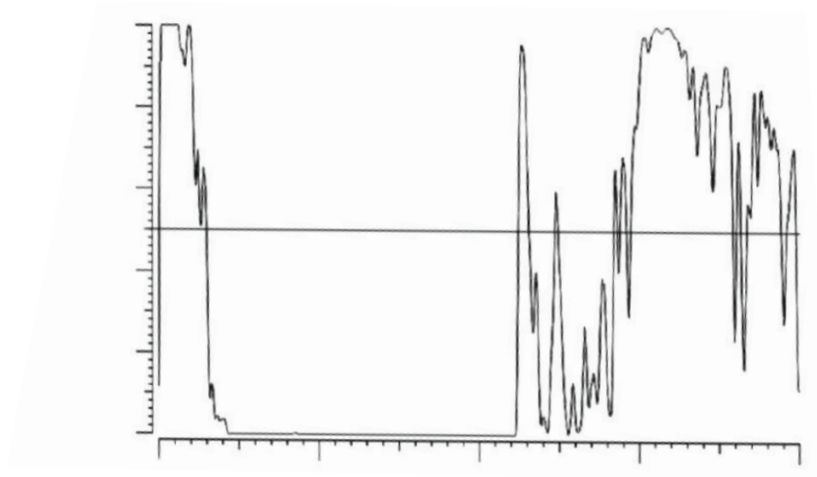
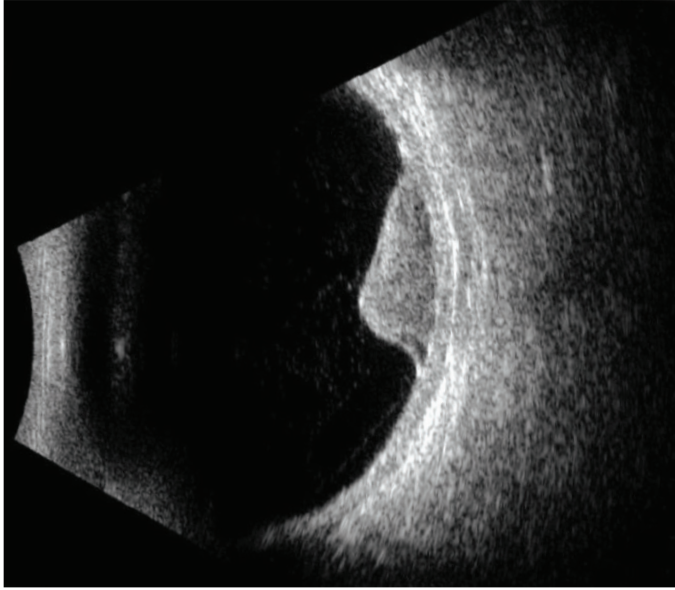
Fig 17: Posterior chamber phakic IOL: axial length measurement is taken with calliper on anterior IOL interface and posterior natural lens capsule.

CONCLUSION

B-mode biometry has a learning curve, but once mastered it can be used for axial length measurement in every clinical situation, with proof of reliability, in particular when optical biometry is not available.

The other advantage of B-mode biometry is that it provides an anatomical overview of the posterior segment of the eye, enabling assessment of the vitreoretinal interface, anatomical analysis of the macular region and visualization of peripheral lesions, which can be hidden by dense cataracts during slit lamp examination.





02

METHODOLOGY OF STANDARDIZED ECHOGRAPHY

INTRODUCTION

“Standardized Echography” is the most important and precise diagnostic method in ophthalmic ultrasound, it is widely used by experts and specialist all around the world. It was initially conceived in 1963 in the 2nd Eye Department at the University of Vienna (Austria), developed and maintained in constant evolution until the present time by Prof Dr. med. Karl Ossoinig and a group of teachers and researchers emerging from the Universities of Vienna (Austria), Iowa (USA) and other medical centers where the disciples have continued using and teaching the method.

The goal of standardized echography is to demonstrate the ultrasound patterns, the histological and histopathological correlation of the normal anatomical structures (eye and orbit), as well as their pathological changes. The main purpose is the “Tissue differentiation”, In other words is the art to interpreting the images “that sound produces when crossing a structure”, correlated these with the internal structure using proven and pre-established patterns validated for years of experience.

The advantage of standardized ultrasound is that it is designed both in the equipment and in the techniques to provide a universal and optimal echographic language with superior, understandable, comparable and repeatable results.

A sequential examination, with logical correlation and use of specific techniques at certain times, allows a safe and orderly data collection, which guarantees an adequate diagnosis.

Intraocular, orbital and periorbital conditions are detected and differentiated with high reliability with this method. Of course it is dependent on the fact that the examination has been carried out with the appropriate equipment (Standardized device, specially designed for this purpose, (i.e. Aviso S and ABSolu S) and also the standardization of examination techniques (perhaps the most characteristic). It is important to mention that someone who has been trained in the subject must perform the examination. (Fig 18.1 and 18.2)

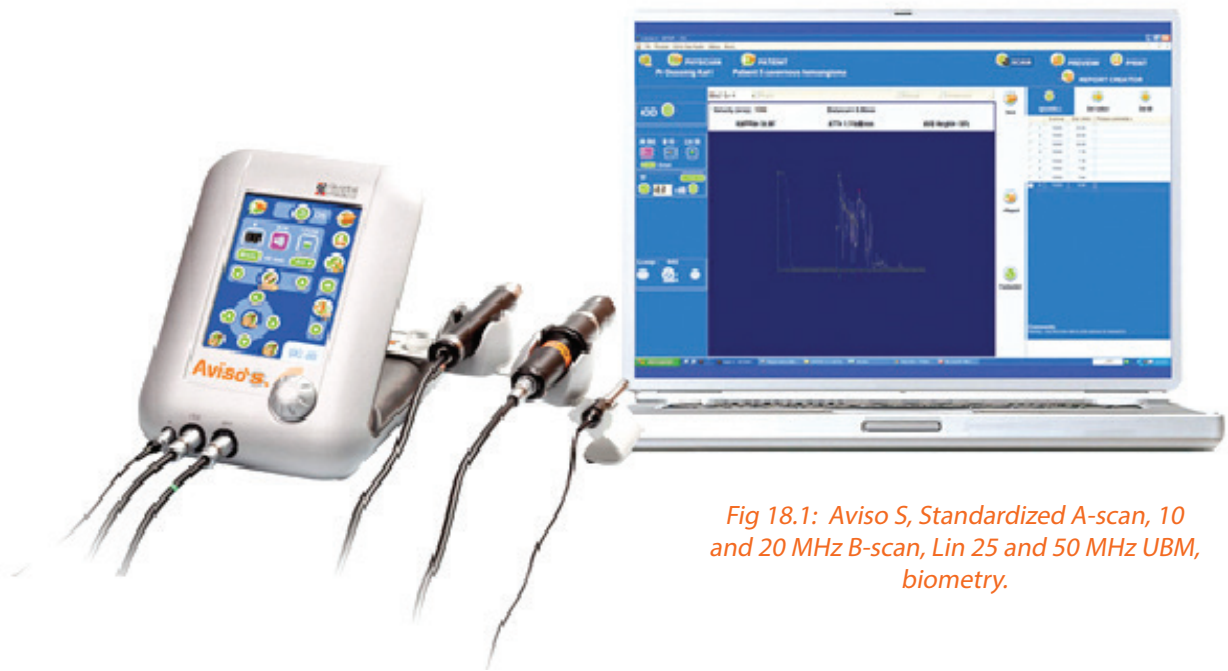

Fig 18.1: Aviso S, Standardized A-scan, 10 and 20 MHz B-scan, Lin 25 and 50 MHz UBM, biometry.

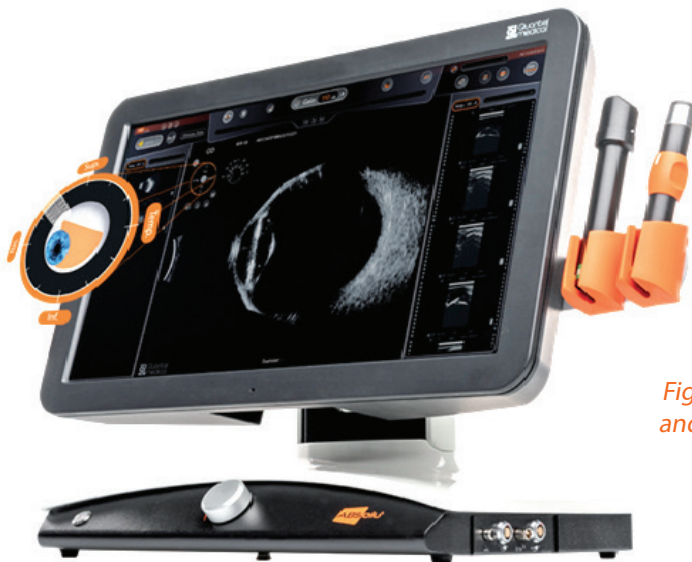

Fig 18.2: ABSolu Standardized A-scan, B 15 MHz and 5 rings annular 20 MHz probe, New Liner 50 MHz for UBM, biometry.

Currently, due to a substantial improvement in the resolution and quality of the images obtained with B-mode, many of the pathological conditions can be easily defined with this method, but when the most accurate determination or intrinsic differentiation is required, the A-scan is extremely important, this occurs in 10 to 20% of the lesions detected only with mode B-scan, but this percentage that is finally defined due A-scan is what makes the difference between the expert and the non-expert.

Standardized A-scan is the most accurate method to differentiate a nevus from a malignant melanoma, is useful in the exact definition of the type of ocular or orbital tumor, the differentiation in complex cases between retinal detachment from a posterior vitreous detachment, especially if there is impregnate hyaloid. It is also a powerful tool to make the determination of retinal detachment immersed within dense hemorrhage (Ghost" R.D") or cases in which peripheral choroidal detachment versus retinal detachment should be differentiated

Standardized echography is a very important diagnostic tool in the orbit even with the availability of advanced forms of imaging such as computed tomography (CT) and magnetic resonance imaging (MRI), this technology is still helpful, and it can reveal the internal structure of lesions better than some of the more advanced imaging technologies. Also is the only echographic method to study Grave's disease, and Optic Nerve Pathology (intraorbital).

So much in eye as in orbit, best measurements are made with A-scan because B-scan measurement are difficult to carry out properly.

Standardized Echography is a combination of:

1. "Real time" contact Standardized B-scan (10, 15, 20, 20 MHz with 5 ring annular array technology, 25 and 50 MHz linear probes)
2. "Real time" diagnostic Standardized A-scan (8 MHz) narrow band, wavelength 0.2mm, in a parallel beam, with the same resolution along the length scan, designed for diagnosis and also used as biometric A-scan
3. At times, a simple non directional Doppler.

Each one of these applications is used at a certain moment of the exam according to each one's optimal suitability.

Standardized echography has a specific design of instrument, probe and signal processing for A-scan, and some specific examination techniques for A and B-scan in order to achieve optimal echographic localization, tissue differentiation and measurements.

If we summarize standardization means: one echographic language, with reliable, understandable, comparable and repeatable optimal results .

A-mode is designed for diagnosis. The parameters for standardization are specific: a probe with a parallel beam, an amplifier with a S curve, a receiver with 8 MHz narrow band and finally a Tissue Model to calibrate the decibel Scale (dB) to determinate "Tissue Sensitivity". Those special characteristics of instrument, techniques and method allow to study the echographic signals according to uniform, stable, and repeatable, parameters, confirmed empirically for more than 54 years of experience.

There are two types of standardization, the internal one, dependent on the equipment and which is determined by the amplification curve in S shape, that amplifies the weak echoes and minimizes the strong ones, and the external one, dependent on the calibration with the tissue mode. This last one reproduce images in a uniform way independently of the waste of the probe. (Fig 19.1)

The external calibration value is obtained, when the image obtained from the tissue model using A-probe, has a decrease in the amplitude of the signals in a pattern whose angle of decrease is 45 degrees. (Fig 19.2)



Fig 19.1: Calibration of the probe to using the tissue model (TM 868) in order to obtain tissue sensitivity.

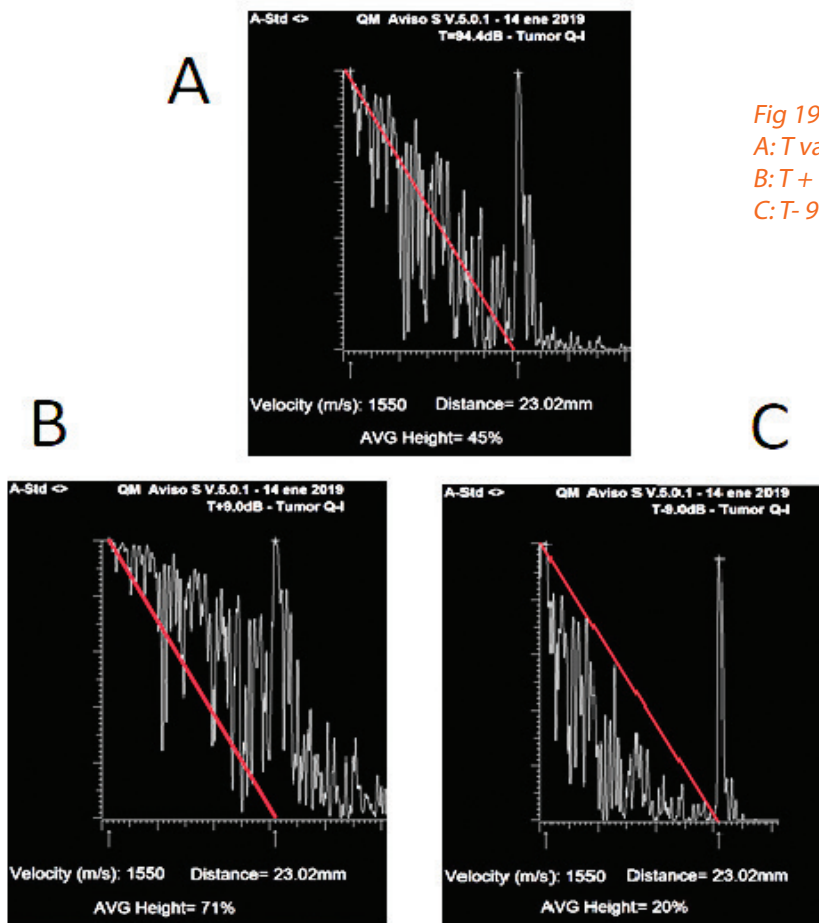


Fig 19.2: Tissue sensitivity.
A: T value (angle of 45°),
B: T + 9 dB,
C: T - 9 dB.

EXAMINATION TECHNIQUES

A systematic approach to intraocular and orbital examinations includes use of the specific basic examination and special examination techniques.

It begins with the «Basic Examination» or «scanning», which serves to detect what is perhaps the most important initial task of anyone who starts in ultrasound: To determine normality or abnormality in the patient, by means of the detection of some pathological changes. Once a lesion is detected with the basic examination, a variety of acoustic criteria are determined with topographic, quantitative and kinetic examination techniques for lesion differentiation, localization and measurement.

Both in A-mode and B-mode scanning, the transducer must be directly applied to the bulbar conjunctiva (contact mode), after application of topical anesthesia, in this way it is possible to have a better penetration and image, avoiding losing energy by the passage of the ultrasound beam through the eyelid. Only in the paraocular examination, of the anterior third of the orbit, the transducer will be placed directly on the eyelid. (Fig 20)

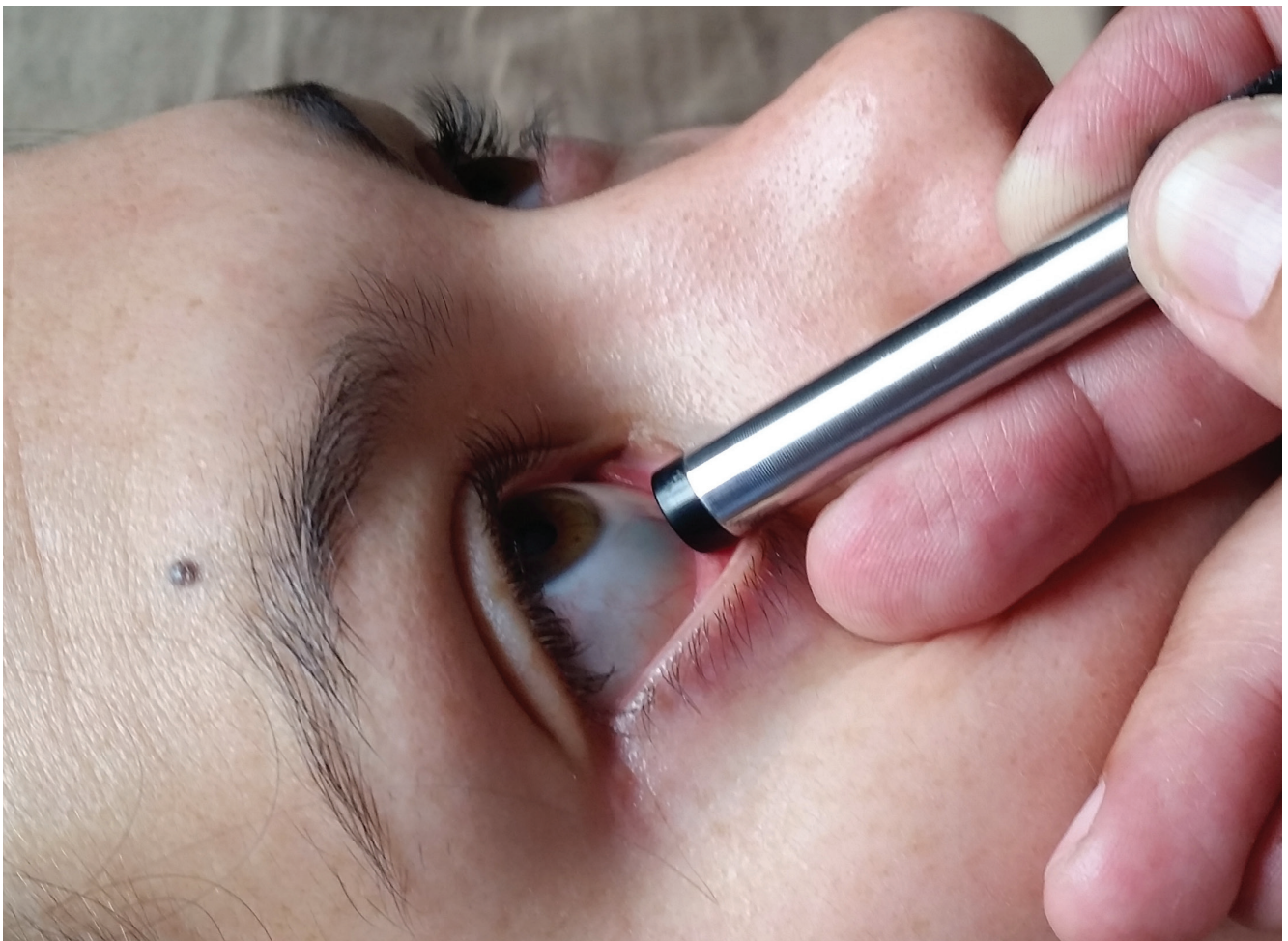

Fig 20: After topical anesthesia, the transducer is placed on the edge of the corneal limbus over the conjunctiva. The patient must look in the opposite direction (extreme look) in this way the ultrasound beam is prevented from traversing the lens and the examiner visually confirms the area being examined.

In the globe, standardized echography is useful in both opaque media, where fundus view is obscured or prevented, and in clear media as a supplement to the ophthalmoscopic examination. Standardized echography is also useful in the evaluation of orbital and periorbital disease. Mass-like lesions, extraocular muscle and optic nerve conditions may be detected, differentiated and accurately measured.

Diagnostic B-scan is utilized for topographic evaluations such as the location of a lesion and its shape, insertions and relationship to neighboring structures, for an estimate of its dimensions across the sound beam, and for kinetic evaluations of some types of the lesion's mobility and consistency.

- B-scan of 25-50 MHz linear probe, is preferred for evaluations of the anterior eye segment,
- B-scan of 10 - 15 and 20 MHz is applied for the posterior eye segment,
- B-scan of 10 MHz is utilized for the orbit with limited penetration because it is generally focused at 23 to 24 mm. (Fig 21.1, 21.2, 21.3)

Actually a new 20 MHz with 5 circular rings allow to have a more defined image with a better depth of field, an increased lateral resolution while retaining the axial resolution. (Fig 22)

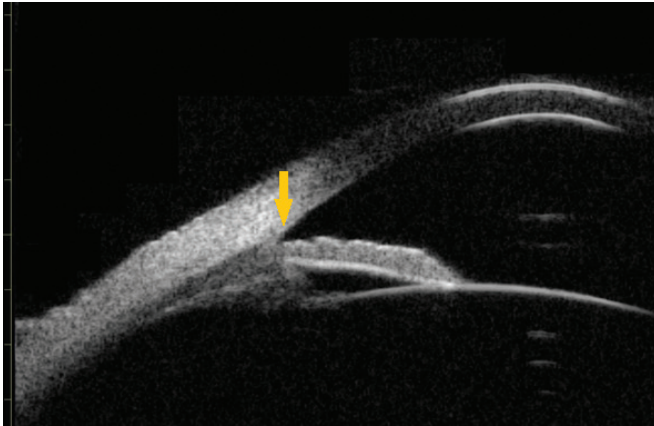


Fig 21.1: Image with the 50 MHz linear probe of the anterior chamber angle and the scleral spur (yellow arrow), in a normal patient.

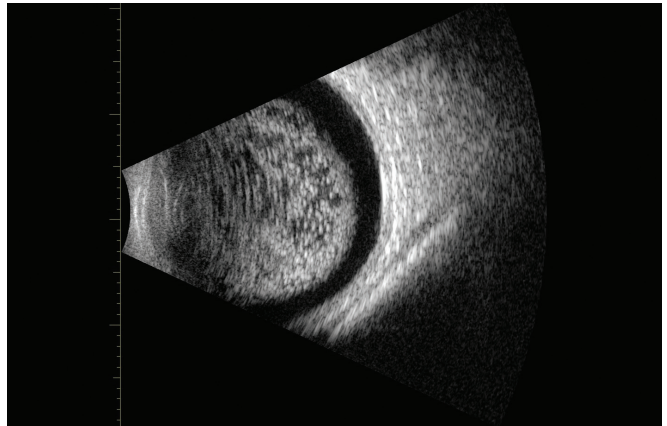


Fig 21.2: Image of asteroid hyalosis using the 10 MHz probe.

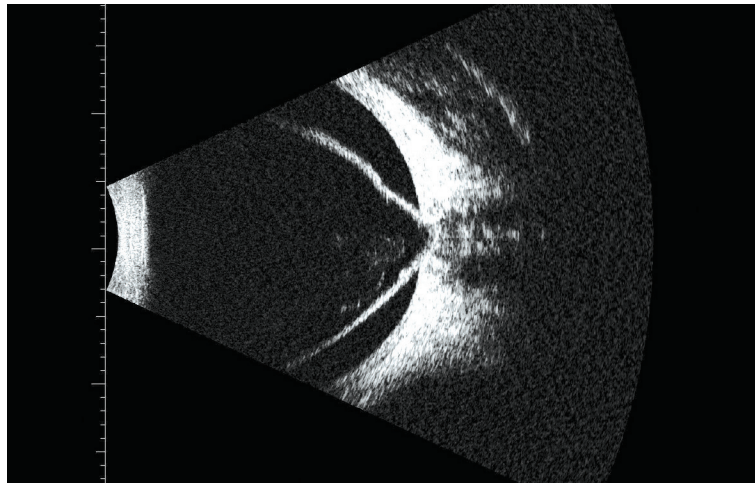


Fig 21.3: Image of a retinal detachment using the BHF P 20 MHz probe.

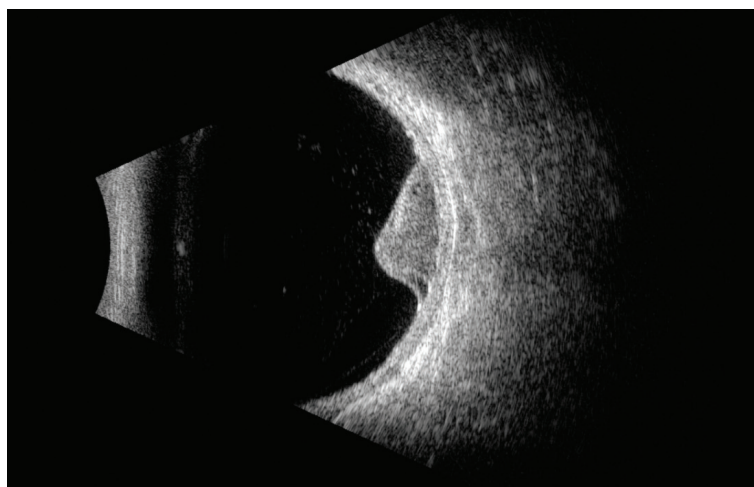


Fig 22: Image of a Malignant Melanoma using the ABSolu's new 5 annular rings, 20 MHz probe.

Diagnostic A-scan (8 MHz effective frequency, parallel beam) is applied for quantitative evaluations of a tissue's structure, reflectivity and sound absorption, for some topographic evaluations such as the borders of orbital lesions or some peripheral insertions in the posterior eye segment, and for kinetic evaluations of a tissue's vascularity, mobility and consistency. (Fig 23.1, 23.2, 23.3)

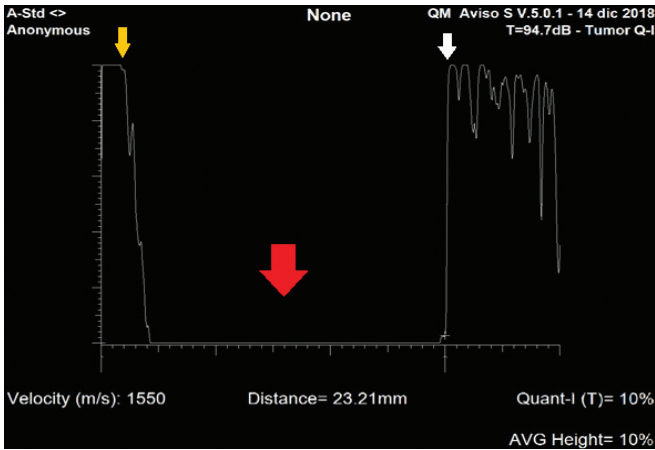


Fig 23.1: Image of the normal eyeball with the standardized A-mode, the initial echo is seen up to 4 microseconds (yellow arrow) then a space of extremely low reflectivity from 4.1 to 30 microseconds corresponding to the vitreous space (red arrow), followed by a sudden rise of an echo of retina, (white arrow) continuing with the ocular wall and the orbit.

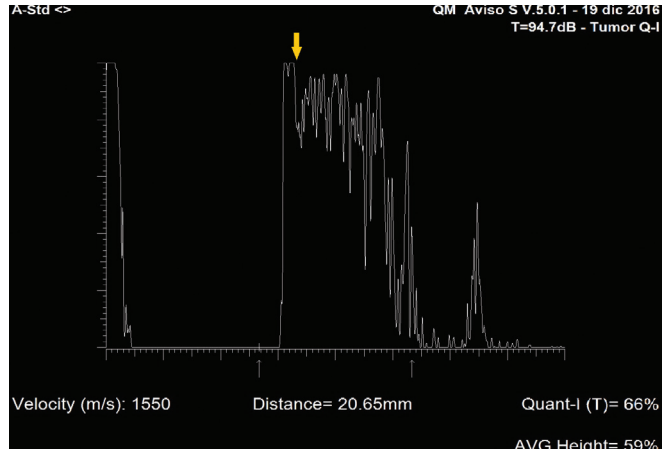


Fig 23.2: A-scan of the orbit: The arrow shows the echo of the sclera; the orbit corresponds to the space behind this echo.

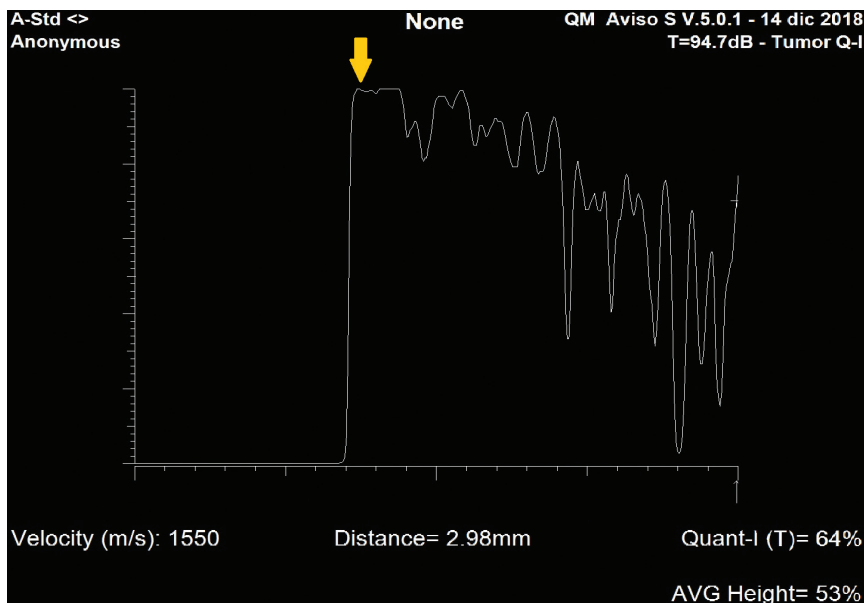


Fig 23.3: Zoom image, in this case focused on the ocular wall (yellow arrow), it helps us to examine in detail the structures, determine the vascularization and for example to see in the optic nerve the layers that surround it.

Biometric A-scan (8 MHz effective frequency, parallel beam) serves precise measurements along the sound beam, for instance the maximal height of an intraocular tumor, the dimensions of an orbital mass lesion, the exact depth of a foreign body, the thickness of tissues such as sclera, extraocular muscles and optic nerve or the distension of its sheaths. The same kind of biometric A-scan is used for most accurate and precise immersion axial eye length measurements for optimal IOL power calculations. (Fig 24)

Pulsed Doppler (at least 9 MHz nominal frequency, preferably of a directional type) may be added for more specific evaluations of blood flow in larger vessels.

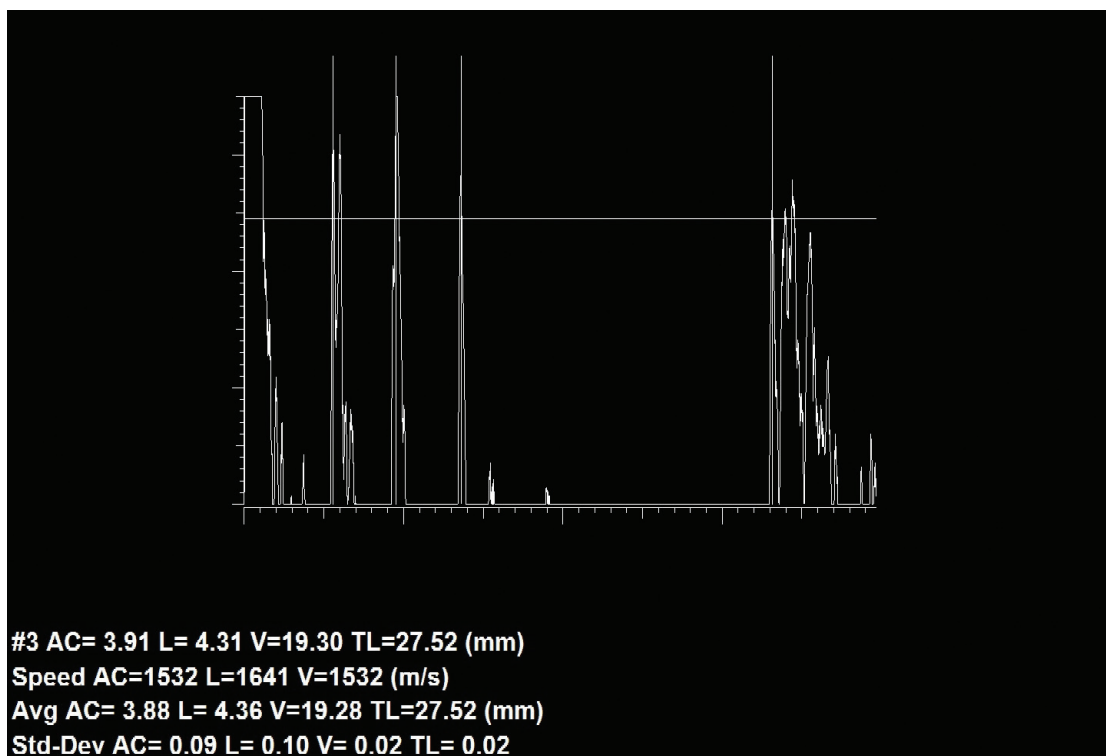


Fig 24: Biometric A-Scan, (Pro beam) immersion axial length.

EYE AND ORBIT BASIC EXAMINATION

It starts with B-mode or the standardized A-mode, using the «tissue sensitivity» («T»). As described in previous paragraphs, this is a calibration and standardization value that is made with a tissue model (Till model) and allows to determine the value of the signal in decibels that will allow obtaining similar patterns among the different examiners.

Attention is paid to the «defects» located after (eye) and behind (orbit) the eye wall.

In A-scan, the eye is seen as an area between the starting echo and the echo of the sclera (the highest reflector of the eyeball), After echoing the sclera, we see an area of about 20 microseconds wide, with signals of high reflectivity and regular-heterogeneous ordering. These decrease gradually from left to right as a result of sonic absorption. (Fig 25.1, 25.2)

In the eye any zone or spike high reflective than base line or a thickening of the ocular wall is a pathological change. In the other hand in the orbit, any zone of low reflectivity or regular-homogeneous structure or a thickening of the echogram, as well as the visualization of the neighboring paranasal sinuses (normally not appreciated for being full of air) show a pathological change.

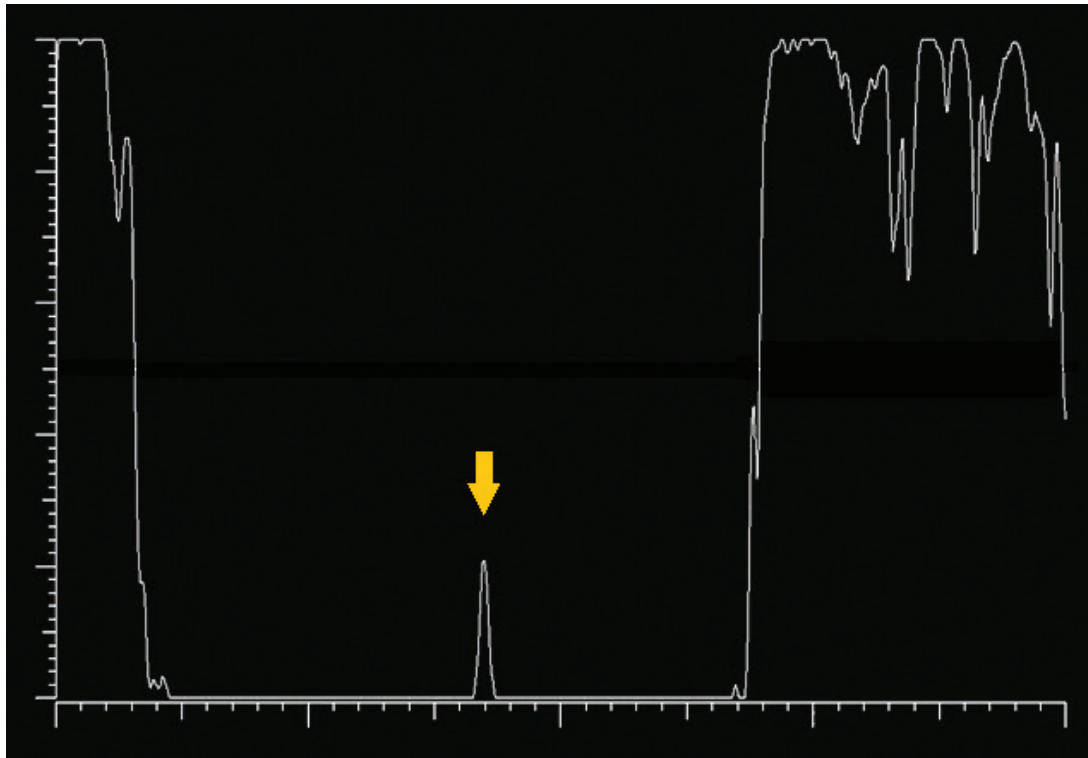


Fig 25.1: The echo emerging from the baseline of the echogram represents detachment of the posterior vitreous (yellow arrow).

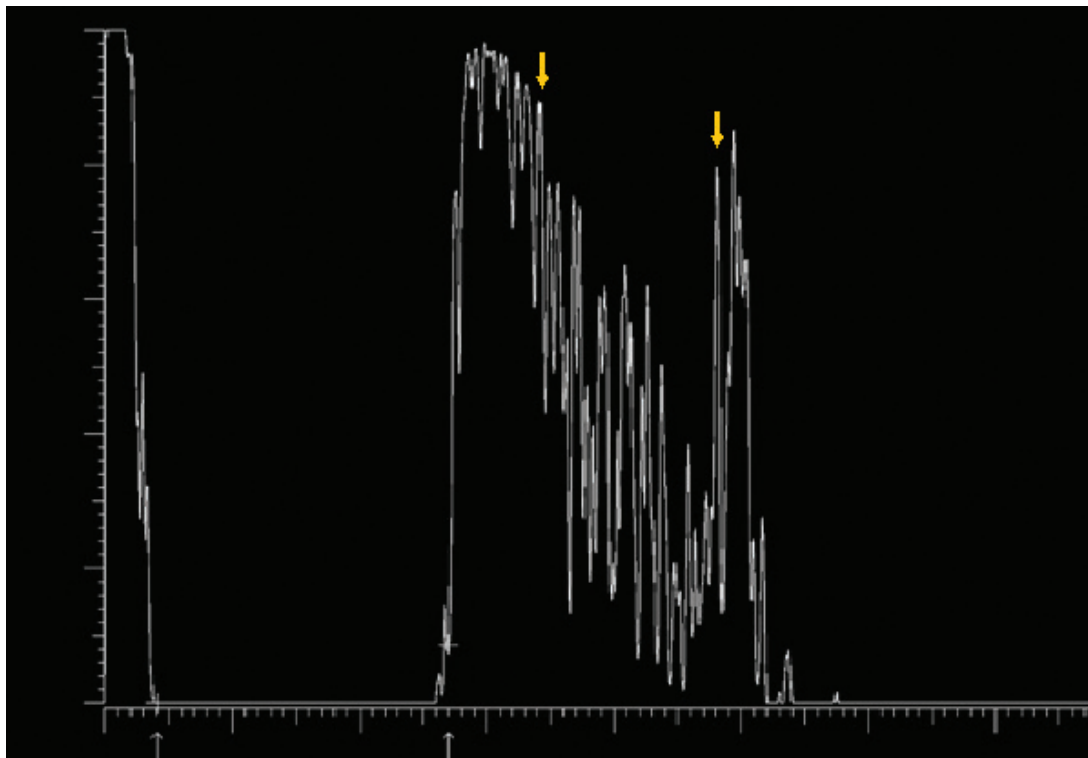


Fig 25.2: in the orbit any zone of low reflectivity or regular-homogeneous structure or a thickening of the echogram shows pathology (space between the two yellow arrows).

POSITION OF THE PATIENT AND THE DEVICE

The equipment, should be positioned in a mobile base easy to disinfect and take anywhere specially to the operating room. Patient must be seated in a reclining chair of adjustable height and degree. The majority of examinations are performed with patient in dorsal decubitus, but sitting positions are very useful in a series of examinations such as when the patient has tamponade with silicone oil. The scanner is located behind the patient's head in such a way that a glance covers both the position of the patient's gaze and the ultrasound screen. Sonographer must be seated in a chair of variable height. You need a reference point on the roof of the exam room. Before each procedure, a drop of topical anesthetic should be applied to both eyes. (Fig 26)

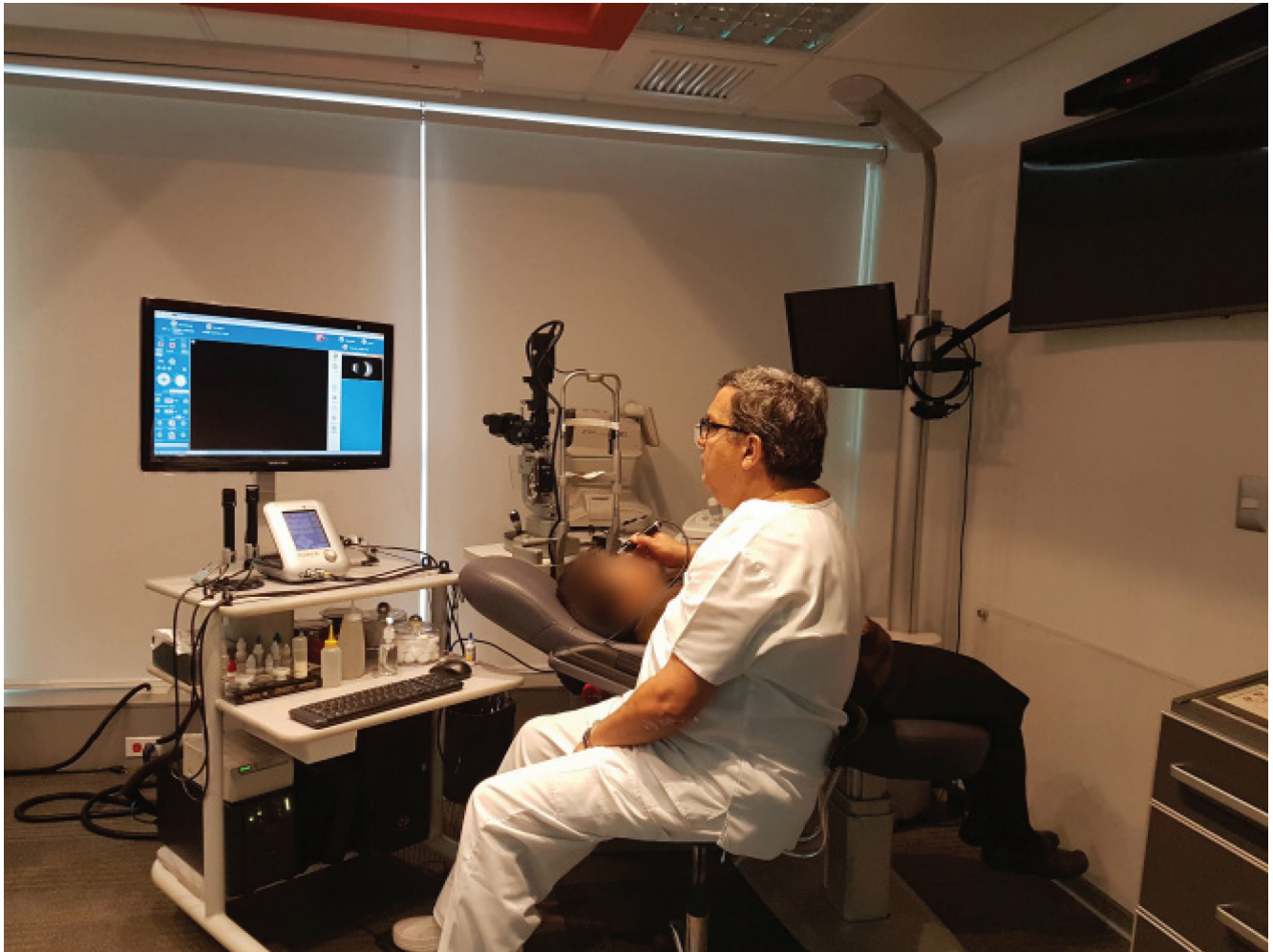

Fig 26: Majority of examinations are performed with patient in dorsal decubitus, sitting positions are useful in a patient tamponade with silicone oil.

BASIC TECHNIQUES: A AND B-MODE.

The first task of the sonographer with both modes is to make a scan of the entire eyeball or orbit and determine normality or abnormality of the structures examined, if during the scan some abnormal structure is observed, it is continued examining through A-mode with the so-called special exams.

The basic scanning test is used to find or rule out a pathological change. It is extremely important to know the normal pattern of the eyeball in both the A-mode and the B-mode, the echosignals found in the acoustically «empty» area (vitreous humor) have a pathological significance in the ultrasound of the eyeball.

A-MODE

The A-mode examines a certain vector of an organ or a tissue, giving us a one-dimensional image. In A-mode there is no mark because it is a parallel beam.

Although the one-dimensional pattern of A-mode makes it particularly difficult for the initial examination, it is always advisable to start practicing this method to make a three-dimensional mental schema starting from a single vector image. In A-mode, the basic test is started by calibrating the equipment to the tissue sensitivity (T). In the case of normality, an initial echosignal is observed, which does not give any information in most cases, then there is an «empty» space corresponding to the vitreous body and behind it several spikes that start with a rapidly rising, smooth signal of very high reflectivity, corresponding to the retina followed by another one that is the one with the highest reflectivity in the globe, which corresponds to the sclera, the echo complex between both corresponds to the choroid. The orbit follows these signals.

Basic examination in both modes is done in 8 meridians, starting at 6 o'clock, with the patient always looking in the opposite direction to the placement of the transducer. Mobilizing the probe from the limbus to the fornix sweeps the entire meridian. The examination is repeated on the other meridians, continuing clockwise in the right eye and against them in the left eye. After the tissue sensitivity test, the same procedure is repeated at lower decibel range (-12 to -24 dB) and at higher decibel range T + 6 or T + 9. In the case of B-mode always starts with the highest decibel range to decrease it if necessary to highlight some structures.

B-MODE BASIC EXAMINATION POSITIONS

For a proper orientation (position of the transducer in relation to the eye and in relation to the ultrasound screen) the transducer has a white line indicating that the area closest to it corresponds to the top of the ultrasound screen. (Fig 27)

In a conventional manner, the transducer mark is placed always pointing upwards or to the nasal region. So we know that what we see on the screen at the top is always superior or nasal.



Fig 27: B-mode transducer line indicates the area shown at the top of the screen.

TRANS AND PARAOULAR SCANNING

To examine both the eye and the orbit, we have, in principle, two types of examinations, the transocular and the paraocular.

A-mode transocular scanning represents the pathological changes of the eye and the middle and posterior thirds of the orbit. (Fig 28)

Anesthetic (drops) is applied to the conjunctival sac, the A-scan transducer is placed at the edge of the corneal limbus, hours 6, directly on the conjunctiva. The patient should look in the opposite direction (in this case 12 hours, extreme look). This exposes the entire conjunctiva in the lower meridian and the transducer travels the entire lower meridian, from the limbus to the fornix. In the path the transducer is kept perpendicular to the surface of the eyeball, simultaneously transducer lateral movements are made to appreciate the para-meridian zones.

In this way we obtain the representation of the opposite meridian in all its extension (meridian of 12 h as well as the neighboring areas 11:30 and 12:30 in the middle and posterior third of the orbit). The examination continues the same on all other meridians. Following the order, the transducer is placed in the lower temporal meridian (right eye = 7:30 hours and left eye = 4:30 hours) so in successive steps 8 meridians are examined.

Para ocular examination has the purpose to represent the pathological changes of the anterior third and the anterior edge of the orbit. The transducer is placed on closed eyelids using a contact medium (methylcellulose) and applying light pressure. First the transducer is oriented in a transocular manner, to then direct it towards the periphery, where it is oriented in the paraocular direction. This easily differentiates the eyeball with a possible lesion of very low reflectivity. The paraocular examination is performed on at least 6 meridians. The transducer «slides» very easily on the surface of the eyelid due to the contact medium. The paraocular examination is started by applying the probe at 12 o'clock, and then placing it at 10:30, 1:30, 6:00, 7:30 and 4:30. Additionally, it is possible to place the small probe in the external and internal edges.

An adequate examination must always be followed by a comparison with the contralateral orbit (meridian by meridian), thus possible asymmetries are detected more easily. (Fig 29)

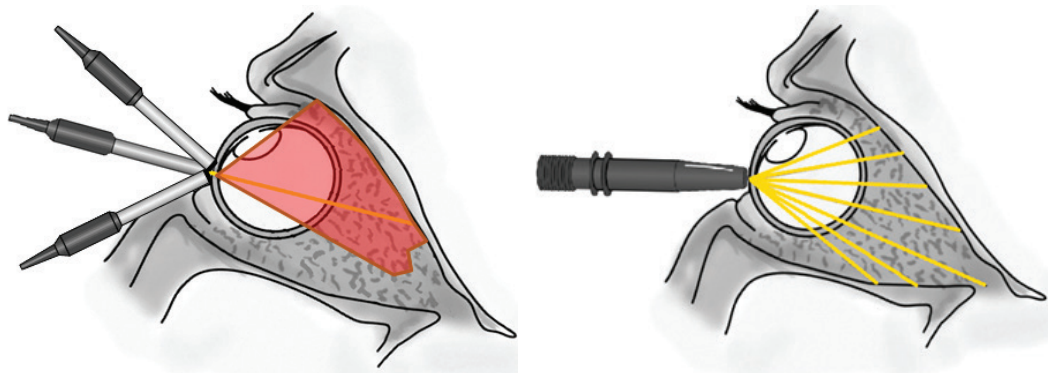


Fig 28: In A and B-mode transocular approach serves us to initially examine the eyeball directly, but and at the same time, we use it to see the adjacent orbit, in this case the eye acts as an acoustic window.

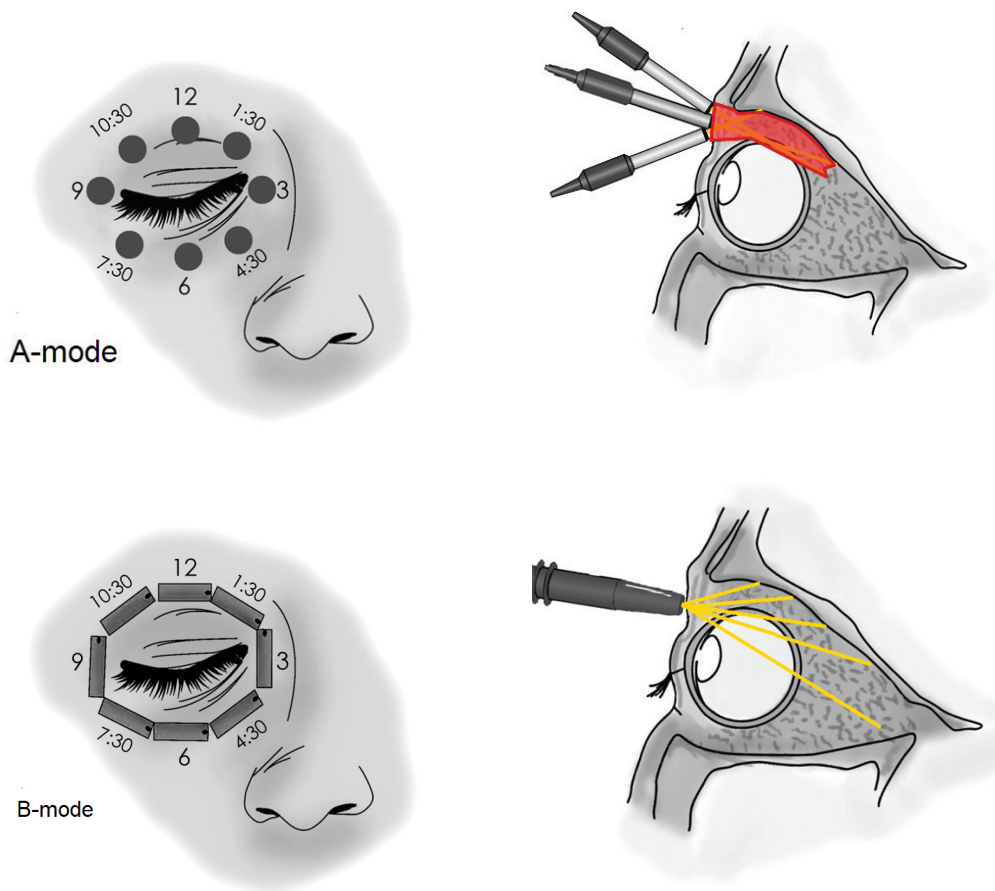


Fig 29: A and B-mode paraocular approach.

B-MODE TYPES OF SECTIONS

Transversal Cross-section

In this section the transducer is placed perpendicular to the meridian to be observed, with the mark upwards or nasal. This means that if we want to examine the eye in the 12 o'clock meridian we must place the transducer at 6hr. perpendicular to the corneal limbus and with the mark pointing nasal area. In this way we obtain an image on the ultrasound screen, in which the upper part represents 3:00 (A) and in the lower part 9:00 (B). In the center of the screen it represents the 12 hours. Together the movement of the transducer from the limbus to the fornix allows us to represent the eye in its different thirds. (Fig 30.1 and 30.2)

The next step is to examine the supero-nasal region, the transducer is placed perpendicular to the limbus in the temporal inferior region (in the right eye at 7:30 and in the left eye at 4:30.) With the mark looking at the superior temporary position. In this position the center of the screen indicates the meridian at 1:30 (right eye) or at 10:30 (left eye) while the top part of the screen corresponds to 10:30 and the bottom one at 4 : 30 (right eye). 1:30 up and 7:30 down (left eye). Next steps are the same in the clock wise direction.

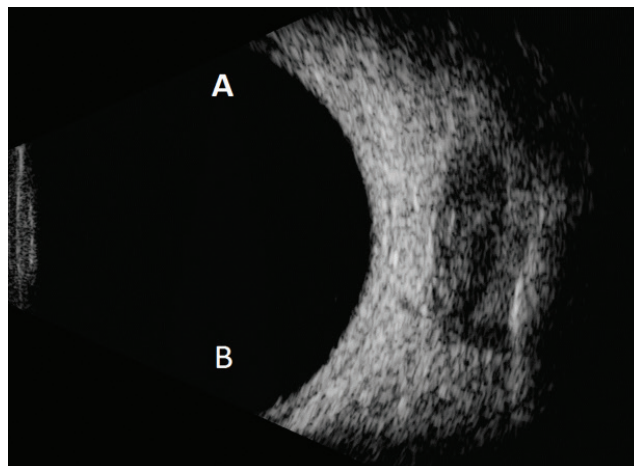


Fig. 30.1: B-mode transducer placed perpendicular to the 12h. meridian, mark nasal, A nasal area, B temporal area, center 12h.

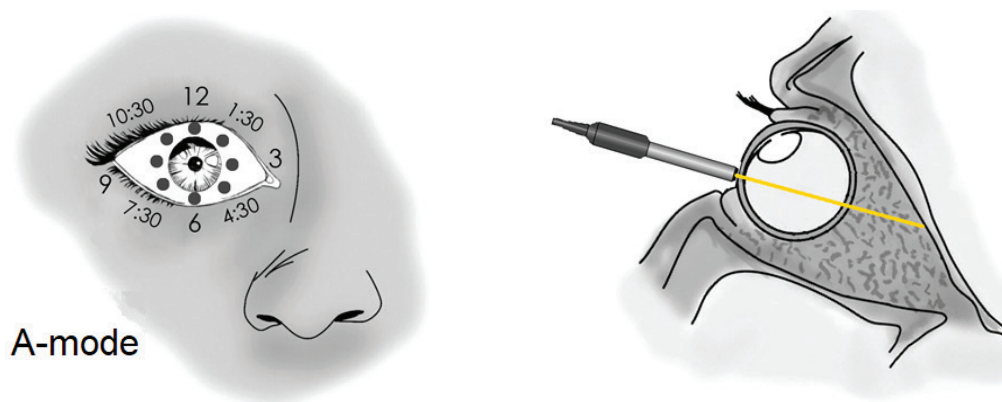


Fig 30.2: A-mode examination: the transducer is located at 6h showing 12h in a transocular scan.

Longitudinal section

In this examination technique, the transducer is moved parallel to the meridian to be examined. For this purpose, the mark on the transducer is placed facing the sclero-corneal limbus, pointing the center of the cornea, as a result we have that the image on the screen represents above the anterior region of the eye and below the posterior pole of the eye. (Fig 31)

For example: If we want to examine the 12 o'clock meridian, we place the transducer at 6 o'clock with the mark pointing to the limbus, so the probe occupies the entire space between the limbus and the fornix. The longitudinal cuts are made in a circular manner presenting some difficulty at 12 hours due to the small space left by the eyelid in that area.

Horizontal-axial and vertical-axial sections

Here the transducer is placed directly on the corneal surface using abundant contact medium. The image obtained corresponds mainly to the papilla or the macula.

In the horizontal-axial cut the transducer mark is placed towards the nasal side. In this way, on the ultrasound screen, the upper zone corresponds to the nasal region, while the lower zone corresponds to the temporal region, thus the echogram is observed, the optic nerve is located in the upper third of the screen, the macula is observed in the center of the screen and in the lower area the insertion of the external rectus muscle appears.

In the vertical-axial section, the transducer mark is placed facing upwards and if the transducer is tilted slightly toward the nasal region, an image with the optic nerve is obtained at the center of the ultrasound screen.

Normally, we do not use this approach, due the distortion caused in the ultrasound beam by the passage thru the lens.

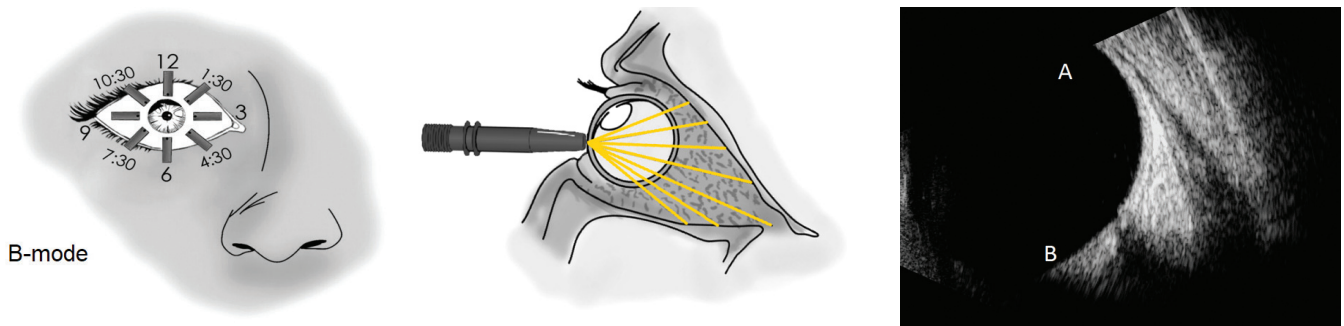


Fig 31: Transducer placed longitudinal to the 12h meridian, mark facing the limbus, A anterior area, B posterior area.

SPECIAL TECHNIQUES

If during the basic examination we find a pathological change we must continue the examination using the so-called «special techniques» of the Standardized Ultrasound in order to locate, measure and perform a differential diagnosis of the lesion.

In order to perform a differential ultrasound diagnosis, all the criteria are evaluated and an integration of the concepts they demonstrate is carried out. For this, it is necessary to evaluate at least 9 echographic criteria that are contained in the following three categories.

Topographic Criteria (Topographic echography)

- *Location*
- *Shape*
- *Size or Borders*

Quantitative Criteria (Quantitative echography)

- *Structure*
- *Reflectivity*
- *Sound Absortion*

Kinetic Criteria (Kinetic Echography)

- *Vascularization*
- *Mobility*
- *Consistency*

TOPOGRAPHIC ECHOGRAPHY

In this case B-mode is much more useful in defining the shape and location of a lesion compared to A-scan, however in the definition of the borders of a lesion, A-scan proves to be superior.

Location

For determination of the location of lesions we are guided by a combination of transversal and longitudinal cuts, that give an adequate three-dimensional representation and establish the relationship of it, with the intraocular anatomical marks, such as the papilla and the lens. The following location criteria are used:

Clock Time, Anterior medial or posterior, Relationship with: Papilla, lens, Insertion of the muscles, anterior and intermediate segment, etc.

Contact B-mode requires that the examiner perform a mental reconstruction of the anatomy in each image he is observing. It is of special importance to remember that the signaling mark of the transducer should always be placed in the nasal direction or upwards, in order to be able to make the determination of the structures that are represented in the upper and lower area of the ultrasound screen.

To locate the intra and periorbital lesions, we orient ourselves by means of the position that this change occupies in relation to the direction of the transducer during the examination and in its vicinity with the orbital anatomical structures. (Fig 32)

Shape

Into the eye the evaluation of the shape of a lesion is variable, whether it is a membranous or solid lesion, we must evaluate the lesion describing its configuration: Rounded, pear-shaped, oval, flat, umbilicated, in collar button, cufflink etc. In addition, the regularity or not of its surface is described. (Fig 33)

The evaluation of the shape of a peri or intraorbital lesion is mainly made by contact B-mode and is characterized under the following parameters:

- Description of the shape (round, oval, in the form of a blood vessel, etc.)
- Regularity of the surface.
- Irregularity of the surface.

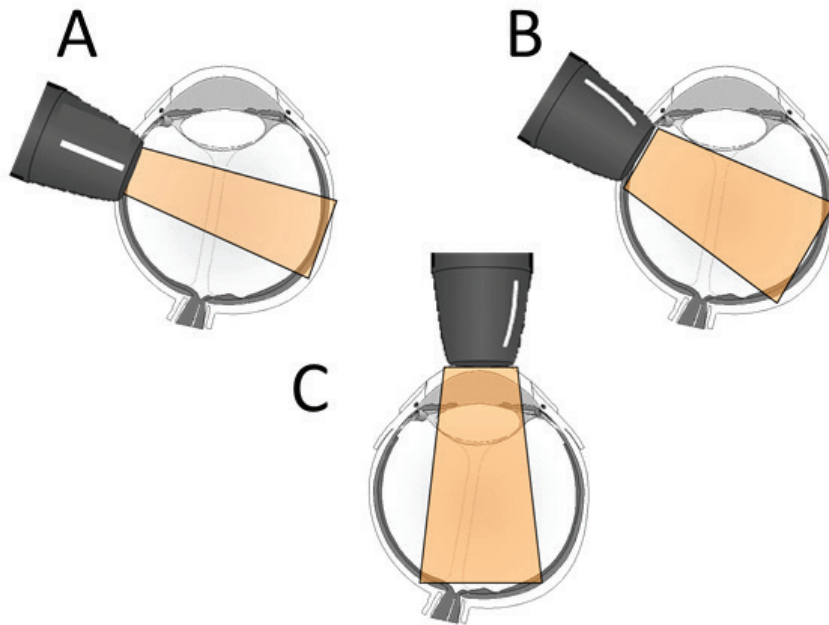


Fig 32: Three types of cuts, (A) Transversal, (B) Longitudinal, and at the end the horizontal axial and vertical axial cuts, (C), in these last two, the transducer is placed directly on the corneal surface and the image obtained corresponds mainly to the optic nerve and the muscular cone.

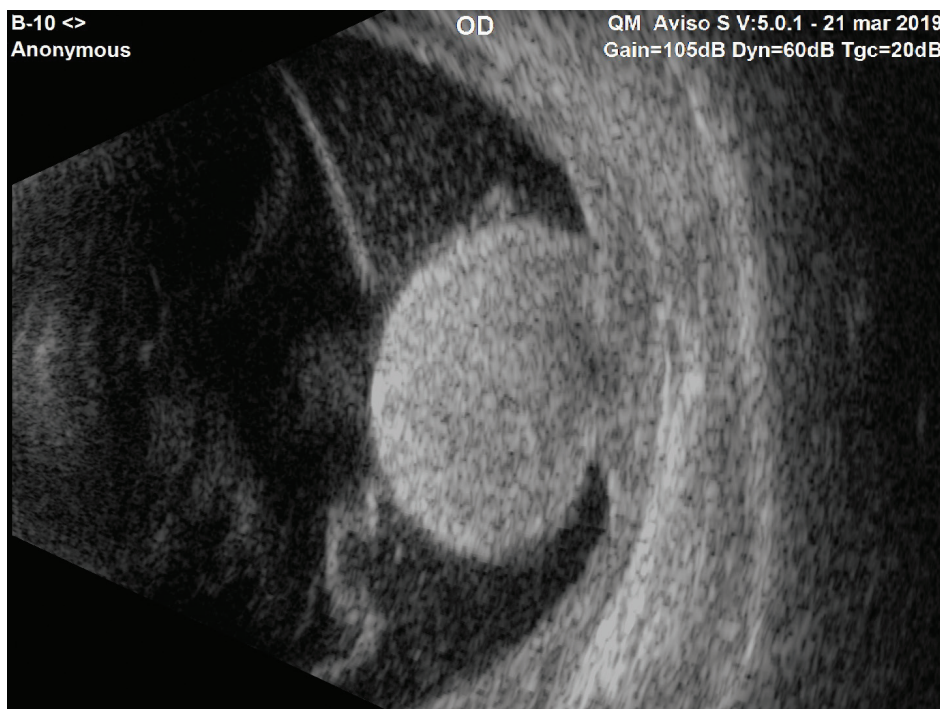


Fig 33: Typical form in "collar button", "champignon" or mushroom shape, this is frequently observed in malignant melanomas of big or medium size.

SIZE OR BORDERS

To determine the size of the lesion we must measure the following dimensions:

- Measurement of the anterior-posterior diameter,
- Transverse diameter measurement
- Measurement of maximum height

Also depending on the case it is possible determine the extraocular extension.

The measurement of the maximum height is basically done with the standardized A-mode technique, since the peculiar representation of the amplitude of the echosignals, like spikes, allows us to measure the distance between the two highest points of these.

The anteroposterior and transverse diameters are measured by means of B-mode as well as extraocular extension.

In the orbit, we must always measure the following dimensions of a lesion:

- Measurement of maximum thickness (transocular)
- Measurement of the maximum depth (paraocular)

The measurements are basically made with the standardized A-mode technique, since the peculiar representation of the amplitude of the echosignals, like spikes, allows us to measure the distance between the two highest points of these.

The size measured with the standardized A-mode implies the use of two types of exam: The techniques for and transocular. In the transocular representation, the maximum thickness is measured, while in the paraocular the maximum depth of the lesion is measured. (Fig 34)

Lesions can present four different types of limits: Fuzzy, not very well differentiated, well differentiated and markedly differentiated. The characterization of the limits is carried out by standardized A and contact B-modes.

An injury has diffuse limits when the surface echo is not clearly observed. The representation of this is a transition area between the zone of low reflectivity of the lesion and the zone of high reflectivity of the ocular or orbital tissue.

The not very well differentiated limits are appreciated as a complex of echosignals that are acceptably well distinguished from the tissue that surrounds it. This complex is fairly wide in the vast majority of cases. The presence of diffuse limits, as well as limits that are not very well differentiated, is observed more frequently in the orbital and periorbital processes of infiltrative nature specially in the orbit.

The well-differentiated limits present both edges (anterior and posterior) with echosignals of very high reflectivity. A single spike-shaped echo and an easily differentiable structure of the surrounding tissue indicates the presence of an encapsulated lesion.

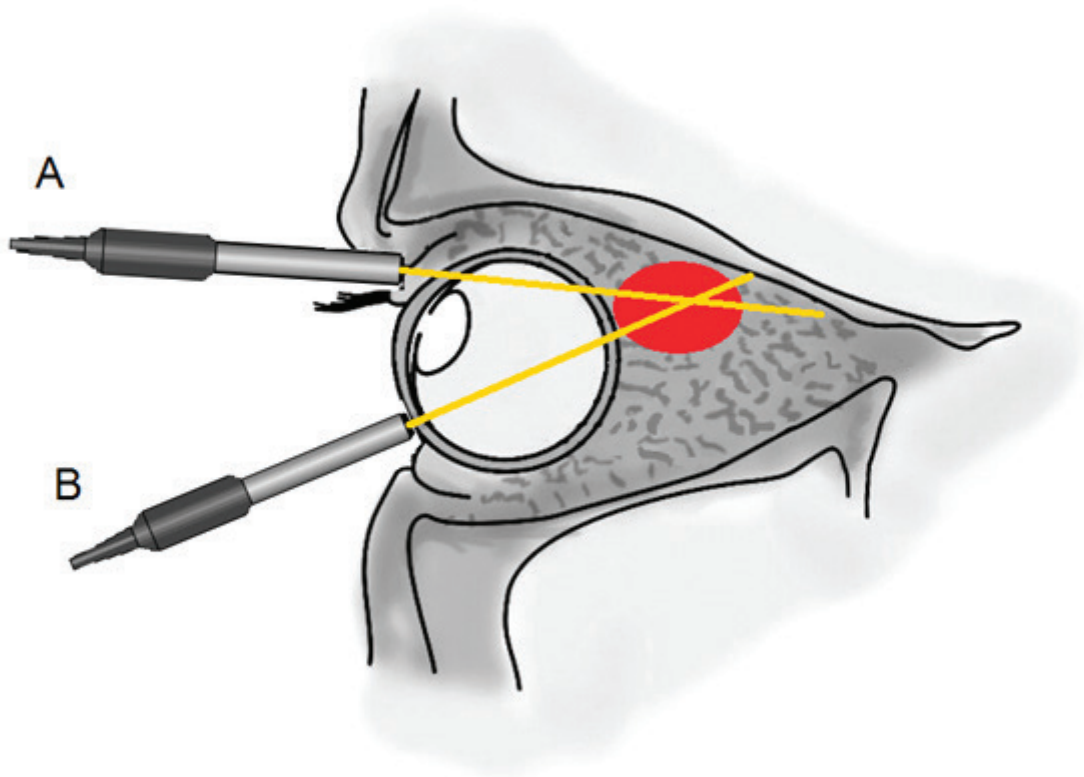


Fig 34: A) Measurement of the maximum depth (paraocular examination) and B) measurement of the maximum thickness (transocular examination).

QUANTITATIVE ECHOGRAPHY

Once the topographic changes have been examined, it is time to determine: The internal sonographic structure, the degree of Reflectivity, and Sonic attenuation (Sonic absorption). Structure is a task easier to perform with A-scan but it is also possible with B-mode, on the other hand the determination of both reflectivity and sound absorption is a task better done with A-mode

Structure

To appreciate the internal structure of a lesion, the order of the echosignals inside the lesion is observed. This ordering can present the following possibilities:

- Regular-homogeneous
- Regular-heterogeneous
- Irregular

In a regular-homogeneous structure all the echosignals have the same amplitude and the same length, or it can be a succession of signals that show a symmetrical and progressive decrease of the amplitude during the echo path. (Fig 35)

Lesions that typically have this structure are tumors with marked cellularity, («compact tumors»), lesions with a very fine histopathological «architecture», and lesions with liquid content.

In a regular-heterogeneous structure the echosignals are arranged continuously, in a regular or almost regular way, presenting a similarity in the length of the signals, but a difference in the height (reflectivity) of them. (Fig 36)

Irregularity in the structure of an injury means that there is an asymmetric ordering of the echosignals, they present, throughout the course of the acoustic wave through the tissue, differences in both height and length. (Fig 37)

Reflectivity

The reflectivity is expressed by the height of the spike obtained to tissue sensitivity and in a perpendicular scan.

There are two types of quantitative ultrasound to determinate the reflectivity.

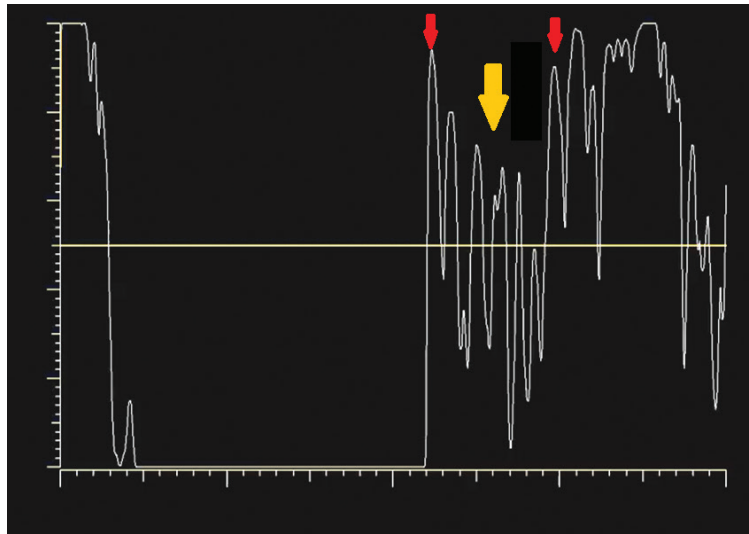


Fig 35: Regular-homogeneous structure, echoes of the same amplitude and same length (yellow arrow), Border of the lesion (red arrows).

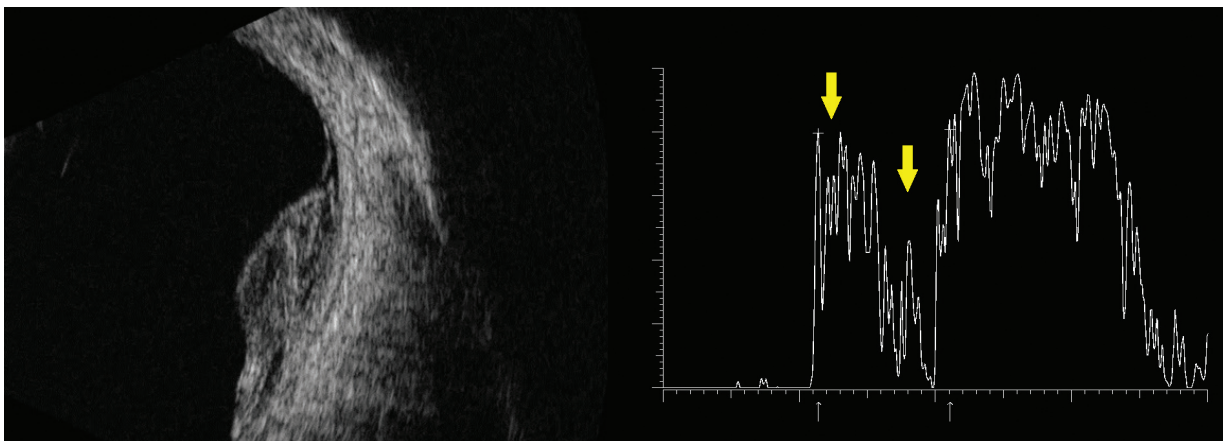


Fig 36: Regular heterogeneous structure: regular zones, differentiated from others that are also regular, but of different amplitudes or lengths, the same lesion with two regular patterns in two different areas of it (yellow arrows).

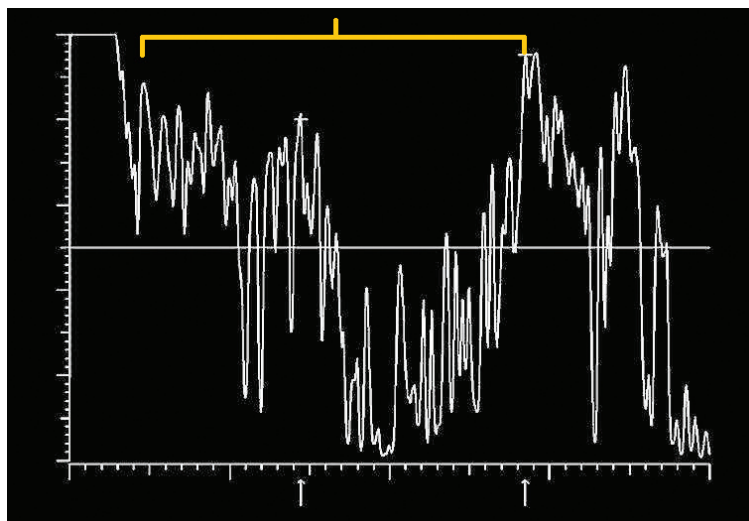


Fig 37: Irregular internal structure, asymmetric ordering of the echoes within the lesion (yellow bracket), both in height and length.

QUANTITATIVE ULTRASOUND TYPE I

It is designed to determine the average of the reflectivity of a lesion, comparing the signal height of the lesion with the maximum height of the echogram of the standardized A-mode: the sclera.

In A-mode the reflectivity is expressed in percentage or descriptive form according to the following table and figures. (Fig 38.1, 38.2, 38.3)

- Extremely high (95 - 100%)
- High (80 - 95%)
- Medium-high (60 - 80%)
- Average (40 - 60%)
- Medium-low (20 - 40%)
- Low (5 - 20%)
- Extremely low (0 - 5%)

In B-mode I is seen as the degree of brightness. This determination should be made in a perpendicular examination of the lesion.

To determine the reflectivity of a lesion, the sonic absorption inside it is taken into account. If the lesion does not present any sonic absorption, the evaluation is made in the total of the lesion. If, on the other hand, the «kappa angle» is observed, one should not fall into the error of considering it as a lesion of low reflectivity, since the absorption has reduced the height of the signals. In lesions with marked sonic absorption, reflectivity should be evaluated in the first 10 to 15 microseconds above of the tissue in question. The surface signal of a lesion is never considered in the evaluation of reflectivity.

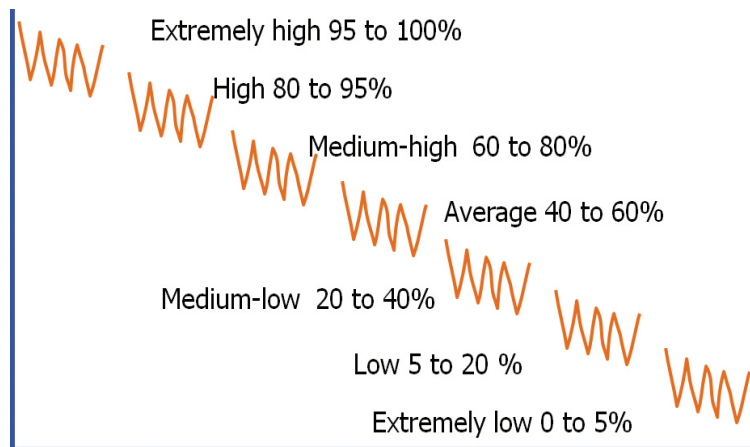


Fig 38.1: The orange waves represent the average height of the internal echos of the lesion.

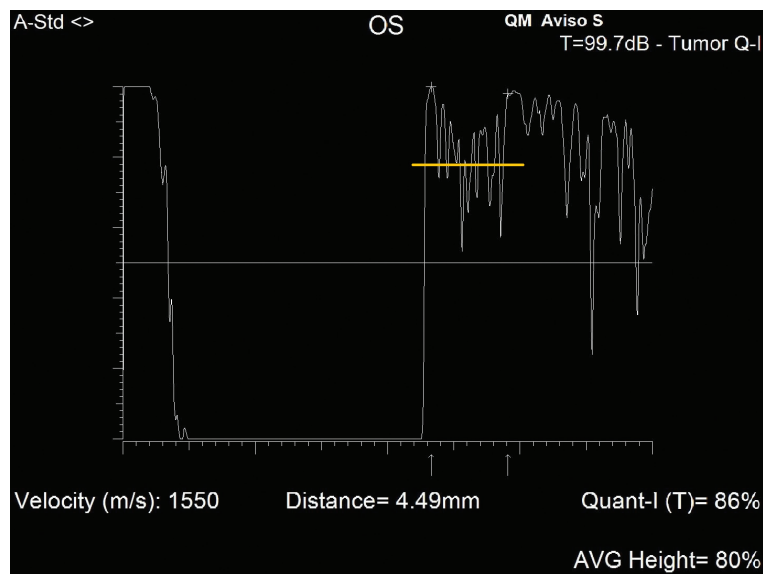


Fig 38.2: High reflectivity, (yellow line: average reflectivity of the lesion).

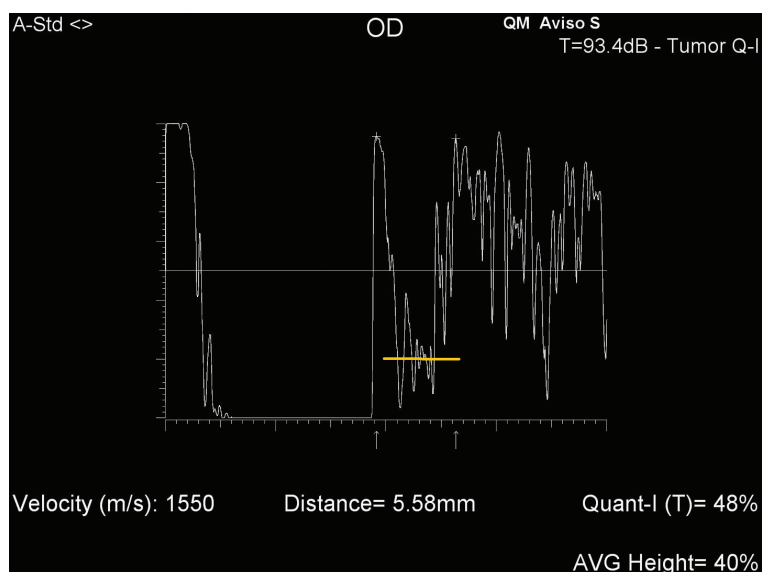


Fig 38.3: Low reflectivity (yellow line: average reflectivity of the lesion).

QUANTITATIVE ULTRASOUND TYPE II

This special type of ultrasound is used exclusively for the differentiation between a dense posterior vitreous detachment and retinal detachment. It is applied when there is a lesion that produces a spike of 100% reflectivity at tissue T sensitivity.

Sonic absorption

The loss of the acoustic wave energy during the path through the tissue to be examined is due in large part to the sonic absorption. This loss is represented as a progressive decrease of the reflectivity inside the examined tissue. The phenomenon of sonic absorption is important in the formulation of a differential diagnosis.

In the standardized A-mode the degree of sonic absorption is described as «kappa angle». If we draw a line from the middle zone of a lesion (or sometimes from the surface echo) and direct it to the baseline (zero line), the angle formed between these two structures is the so-called «kappa angle» and reflects the degree of sonic absorption according to the following table and [Fig 39.1, 39.2](#).

- Sound absorption marked angle $> 45^\circ$
- Sonic absorption moderate angle $= 45^\circ$
- Weak sound absorption angle $< 45^\circ$

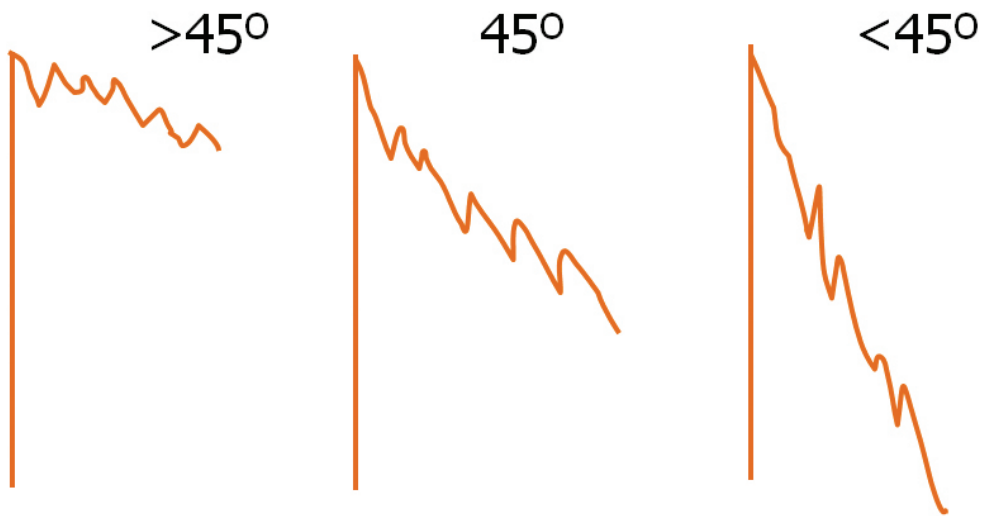


Fig 39.1: The sonic absorption is plotted as a succession of echoes that decrease behind the anterior edge of the lesion, it is classified in degrees depending on the angle of fall of the echoes.

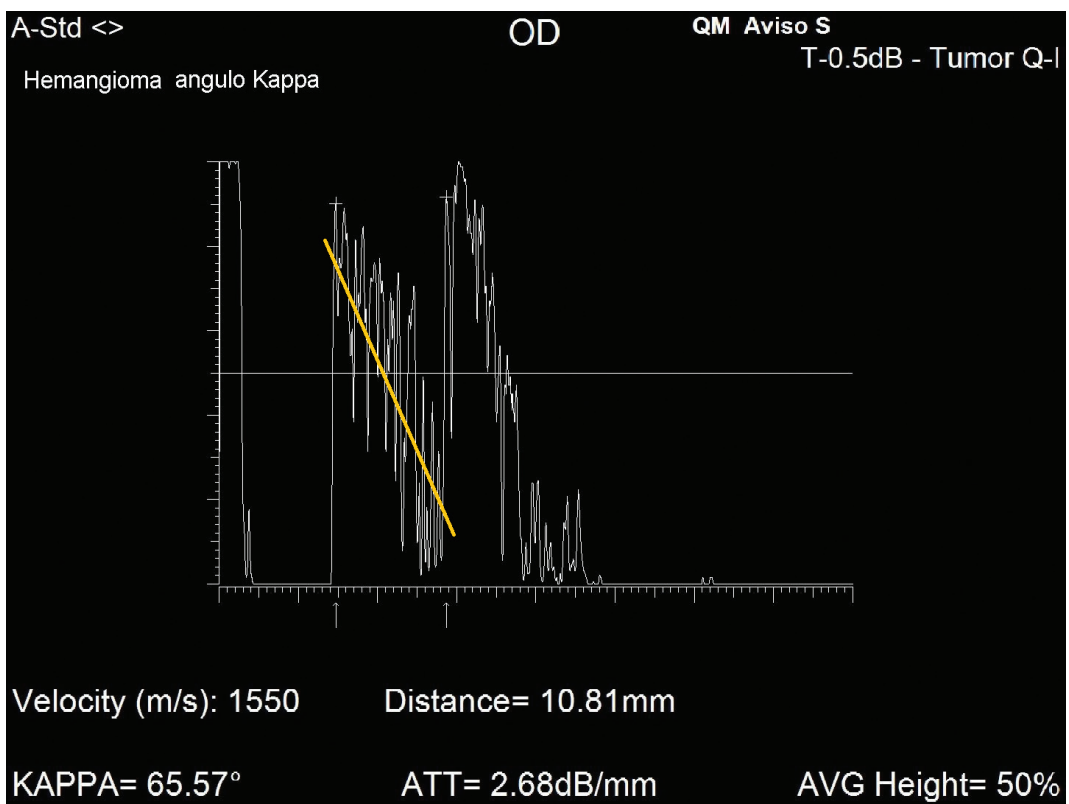


Fig 39.2: Moderate sonic absorption, angle equal to 65° , (yellow line: average absorption of the lesion).

KINETIC ECHOGRAPHY

It is responsible for demonstrating the vascularization (A-scan) , mobility (A and less effective B-scan) and consistency (A better than B-scan) of the lesion.

By means of kinetic ultrasound, the following criteria are examined:

- Mobility, (Post-movements)
- Spontaneous internal vascularization,
- Consistency.

The standardized ultrasound method, unlike other methods of diagnostic imaging, is a real-time method that gives us dynamic information on injuries.

Mobility (Post-movements)

In this case the B-mode of contact provides an excellent representation of the gross movements of the vitreous opacities and membranes. Post-movements are evaluated as their name indicates, immediately after a movement of the eyeball. In A-mode post-movements are classified as horizontal and vertical.

The mobility of a lesion inside the orbital tissue, the following technique is used: Through the transducer, a gentle pressure is applied on the eyeball directly in the position where the lesion has previously been located. Simultaneously, the echogram should be observed to determine any decrease in size (compressible lesion) or displacement (mobile lesion).

Spontaneous internal vascularization

Vascularization is a characteristic of tumor lesions, it is especially useful in determining the standardized A-mode, but in some cases the B-mode. In the determination of vascularization, the eye must be in resting position. The interior of the lesion of low reflectivity is searched for with spontaneous, rapid and constant movement. These represent areas of blood flow. (Fig 40)

While in the eye only A-mode is used to determine vascularization, in the orbit , both the standardized A-mode and the Doppler ultrasound are used to demonstrate it inside the lesion.

With the standardized A-mode, low-reflectivity echosignals should be sought, which presents a spontaneous, rapid and constant movement to the interior of the lesion. These movements are representation of areas where there is blood flow. These signals are described as «oscillating» presenting a very fast movement in vertical direction. A typical example of this in orbit is the arteriovenous fistula, and in eye malignant melanoma intra tumoral vessels.

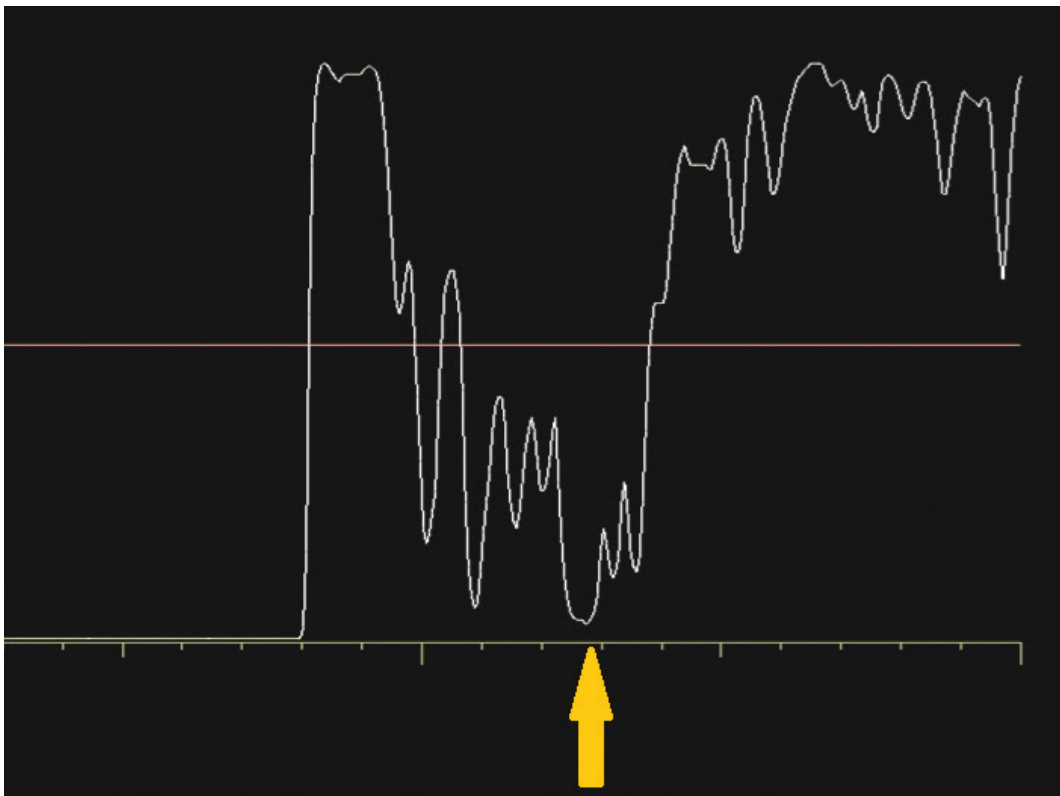


Fig 40: The internal vascularization is observed as an image of very low reflectivity (appearance of a blood vessel with liquid content) and in the deepest zone (yellow arrow) an internal vibration is observed.

CONSISTENCY

In the orbit to test the consistency of a lesion, transocular test is used. By means of the A-mode transducer, a slight pressure similar to that used in the determination of mobility is performed, seeking to compress the lesion between the eyeball and the orbital bone wall. The pressure should not be continuous, but should be carried out in short intervals. (Fig 41)

When the lesion is of «soft» consistency, the echogram decreases in thickness in a clear manner, whereas in the presence of a «hard», non-compressible lesion, no change in the echogram is observed.

Four criteria related to consistency should be observed:

- Extremely hard consistency,
- Hard consistency (possible to be compressed in time, but with difficulty),
- Soft consistency,
- Extremely soft consistency (almost immediate collapse to pressure).

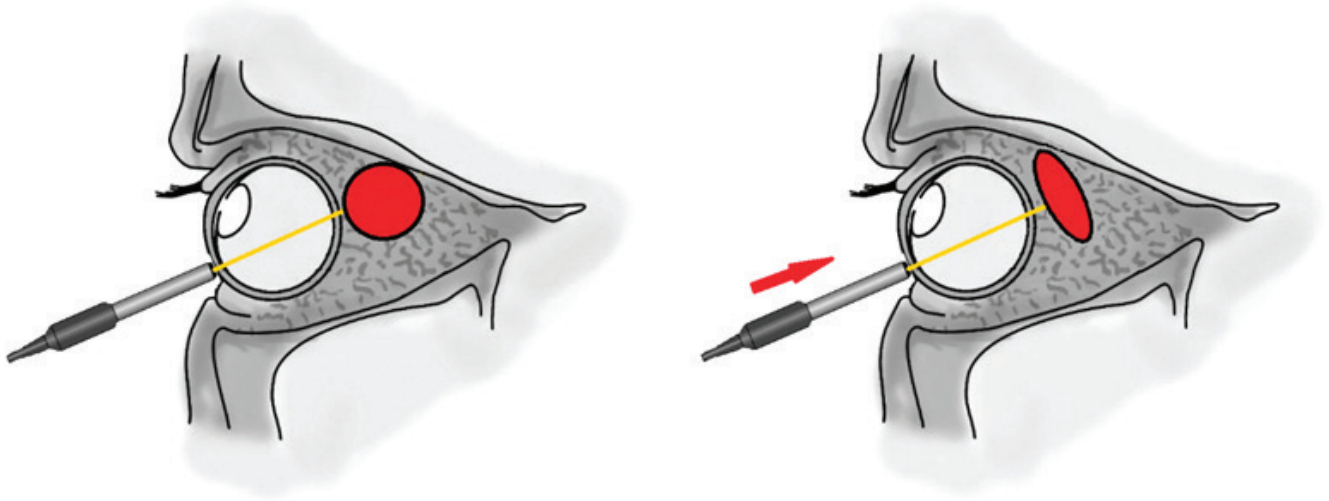


Fig 41: In a «soft» lesion, the echogram decreases in thickness in a clear manner, while in a «hard», non-compressible lesion, no change in the echogram is observed.

A AND B-MODE IMAGE

The spike that rises suddenly after vitreous corresponds to the anterior surface of the tumor covered by the retina and has a 100 percent reflectivity, which indicates that the sonographic beam is arriving perpendicular to the lesion.

The second 100% reflective spike corresponds to the posterior limit of the lesion, the area between them marked by a «bracket», is the internal structure of the tumor.

Between these two signals it is seen that the average of the internal echoes is close to 15% of the total amplitude, which indicates that the lesion has low reflectivity signals inside, in addition two zones are seen where the echo decreases and forms two depressions, these are the internal vascularization areas of the tumor and in a dynamic examination a vibratory movement would be seen inside.

In B-mode, this information is complemented with a description of the rest of the characteristics of the lesion and the structures that surround it, in this case highlighted with circles and arrows.

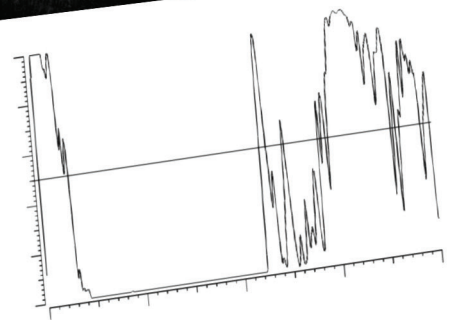
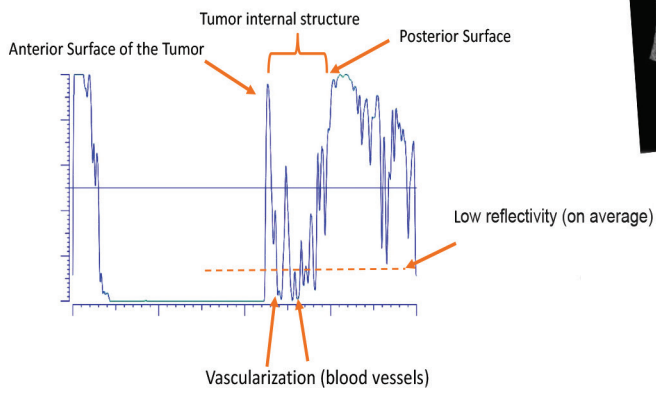
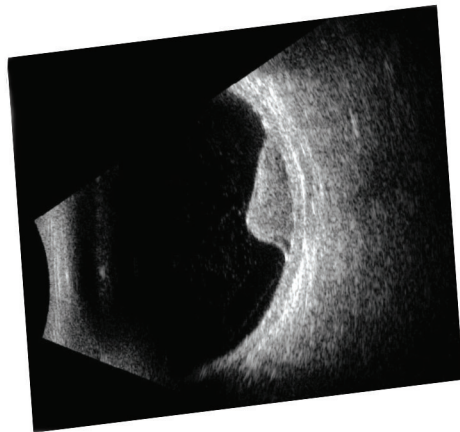
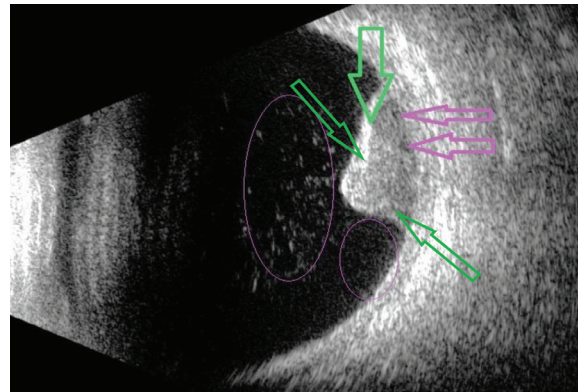
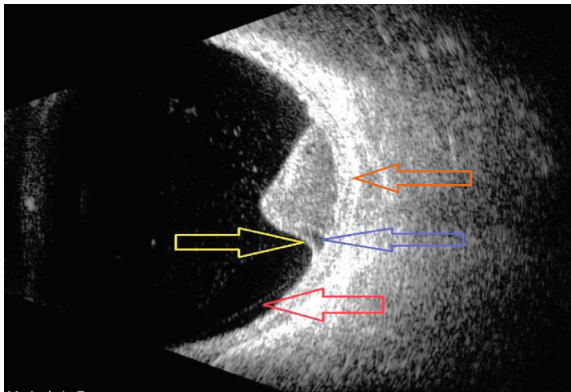
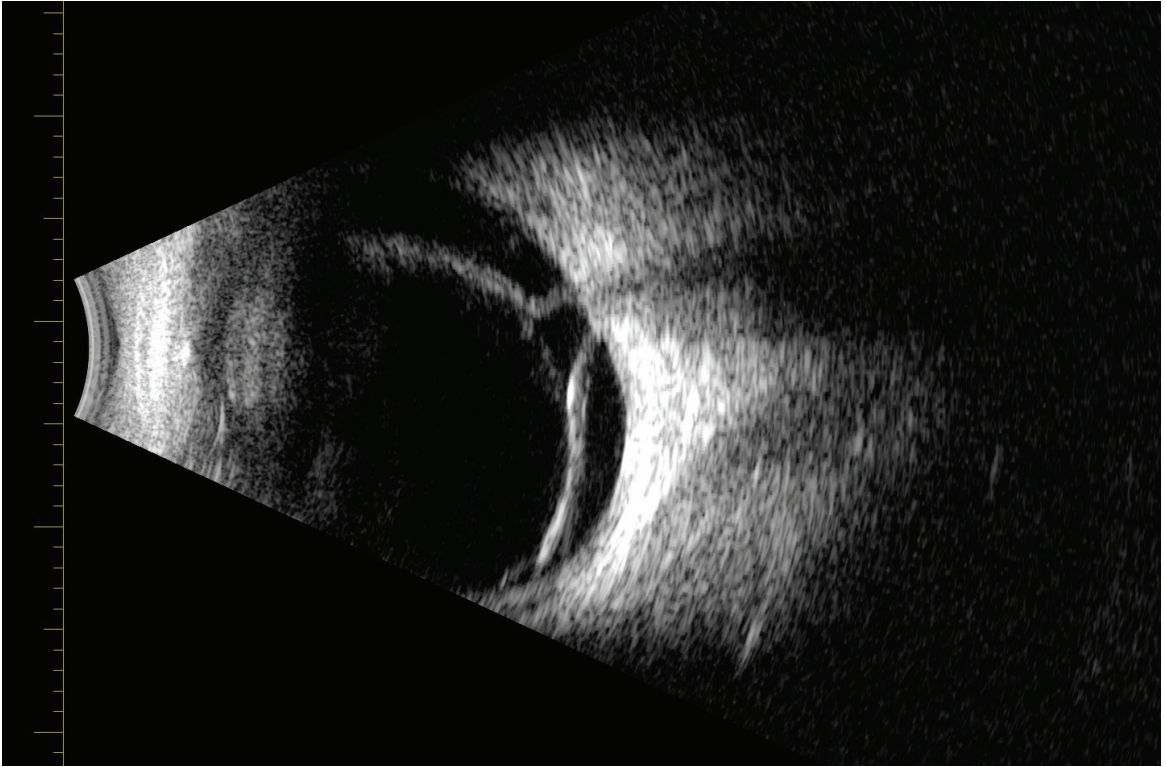


Fig 42: Example of how to integrate the information obtained with A and B mode, in a case of tumor of the posterior pole, in this case a malignant melanoma of choroid.



03

VITREORETINAL
& ORBIT

ULTRASOUND IN VITREO RETINAL DISORDERS, UVEAL INFLAMMATION, OPTIC DISC/NERVE ANOMALIES, AND ORBITAL PATHOLOGY.

The principal use of ocular ultrasound is in the identification of vitreous and retinal abnormalities in opaque media. When there is no view of the fundus due to corneal opacity, cataract or vitreous hemorrhage, or in the case of ocular trauma. Before treatment of the media opacity can occur (corneal graft, cataract surgery, or vitrectomy) it is important to know the state of the retina. In the case of spontaneous non-diabetic vitreous hemorrhage there is a high probability of retinal tear. The B-scan ultrasound can identify retinal tears and associated vitreoretinal traction. If a retinal detachment is present the ultrasound can identify whether the detachment is rhegmatogenous, exudative or tractional. Retinoschisis can also be identified. Any associated choroidal or retinal lesions can be identified. The presence of choroidal detachment and sub choroidal hemorrhage following surgery or trauma is an important role for ultrasound. The presence of posterior scleral perforation can be identified using ultrasound as can the presence of intraocular foreign bodies.

Vitreous abnormalities such as syneresis, hemorrhage, inflammatory cells, or infection can be identified using ultrasound. In particular the B-scan ultrasound has an important role in the diagnosis and management of endophthalmitis.

Inflammatory uveal disease such as posterior scleritis, uveal effusion and uveitis can be evaluated as well as orbital inflammation and infection. Ultrasound of the orbit can be useful in optic nerve abnormalities such as optic neuritis, papilloedema, glioma, and optic nerve hypoplasia when the probe is held at the lateral canthus parallel to the limbus. Evaluation of extraocular muscle abnormalities such as thyroid eye disease, myositis and intra-cornal lesions is also possible.

B-scan ultrasound is performed in an axial, transverse or longitudinal mode. Axial views are generally performed either directly on the cornea or through the eyelid avoiding the lens (except for B-scan biometry). The marker on the probe which indicates the top of the display screen is held pointing towards 3 o'clock or 9 o'clock depending on the eye being investigated. Images of the disc and macula can be obtained using the axial view. Transverse or limbus parallel images are indicated for the screening of the eye in opaque media as they can perform overlapping scans covering 98% of the globe. Longitudinal scans use the probe marker in such a way as to scan through the cornea in the direction of clock hours where the probe is held at the opposite clock hour to the area of interest which will appear in the middle screen when the subject looks towards the area of interest.

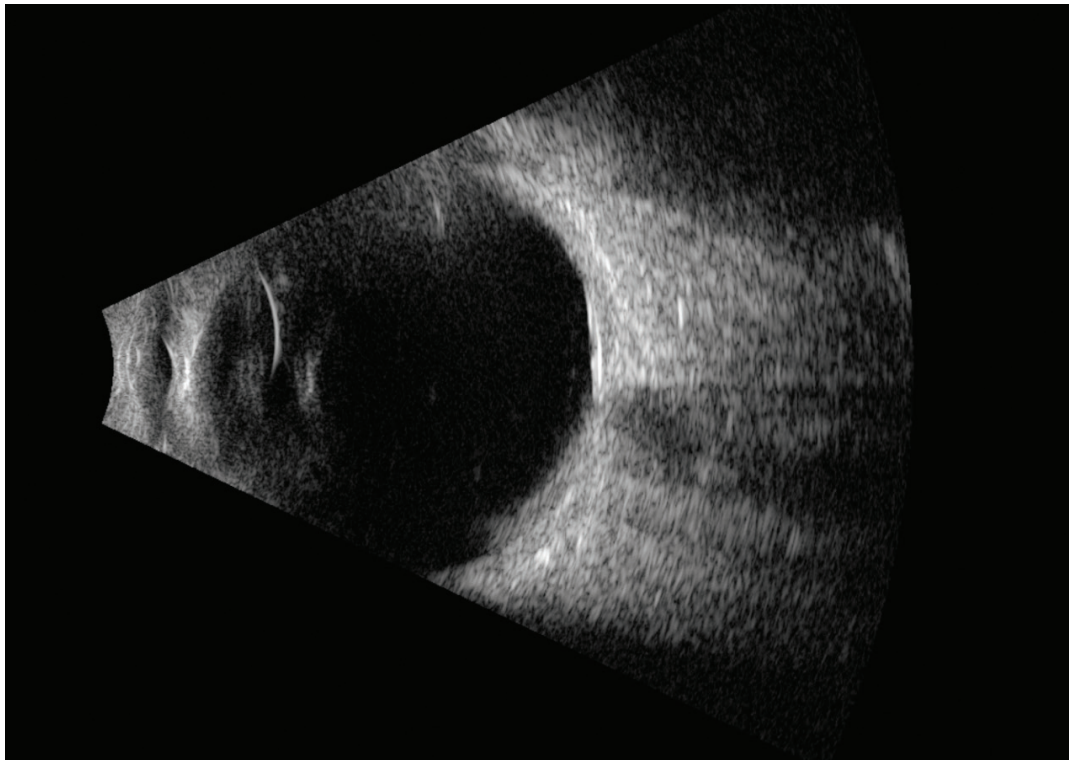


Fig. 43: 15 Mhz image of the whole globe with a carbomer gel on the cornea giving an image which includes the cornea, lens, vitreous, foveal pit, sclera, optic nerve and anterior orbit. This image can be used for accurate B-scan biometry.

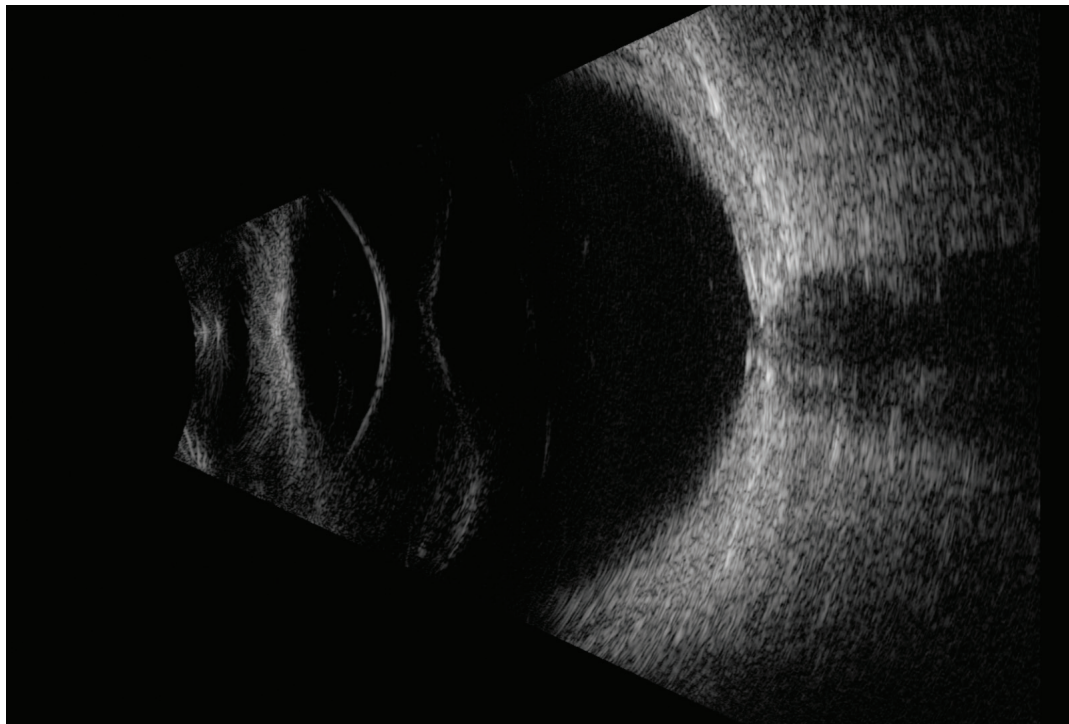


Fig. 44: The same image using an annular 20 MHz probe. Note the whole lens including the posterior capsule can be imaged as well as greater detail of the sclera, tenons space and the optic disc.

Fig 45.1: 20 MHz annular image of the macula. Note 5 layers of the retina can be identified as well as the choroid and sclera. Tenon's space can also be identified.

Fig 45.2: Deep staphyloma in a patient with an axial length of 25.6 m.

Note also the dome shaped macula.

Fig 45.3: Dome shaped macula in a high myope.

This can often be confused with a macular lesion. The homogeneous appearance and scleral reflectivity distinguishes it from a lesion.

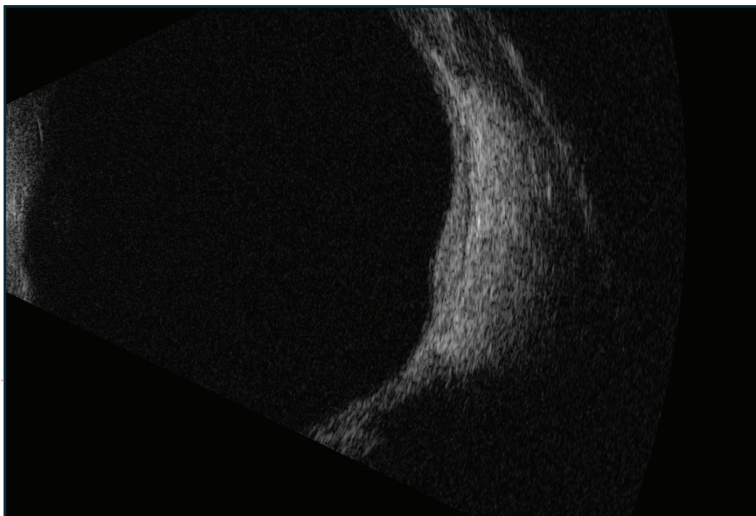
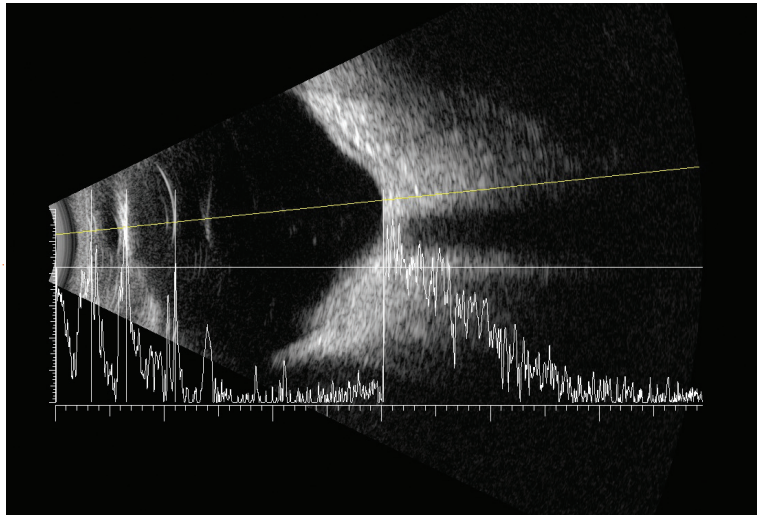
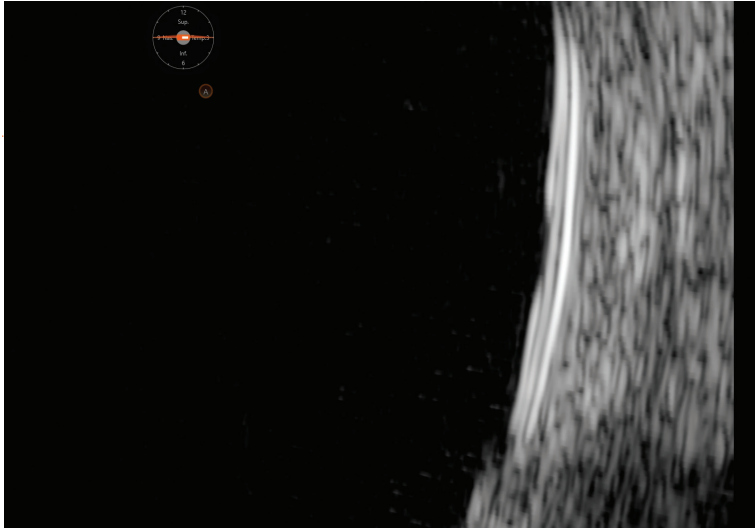


Fig 45.4: Immersion B-scan biometry.

Fig 45.5: Vitreous syneresis in a high myope.

Note the irregular reflectivity within the vitreous.

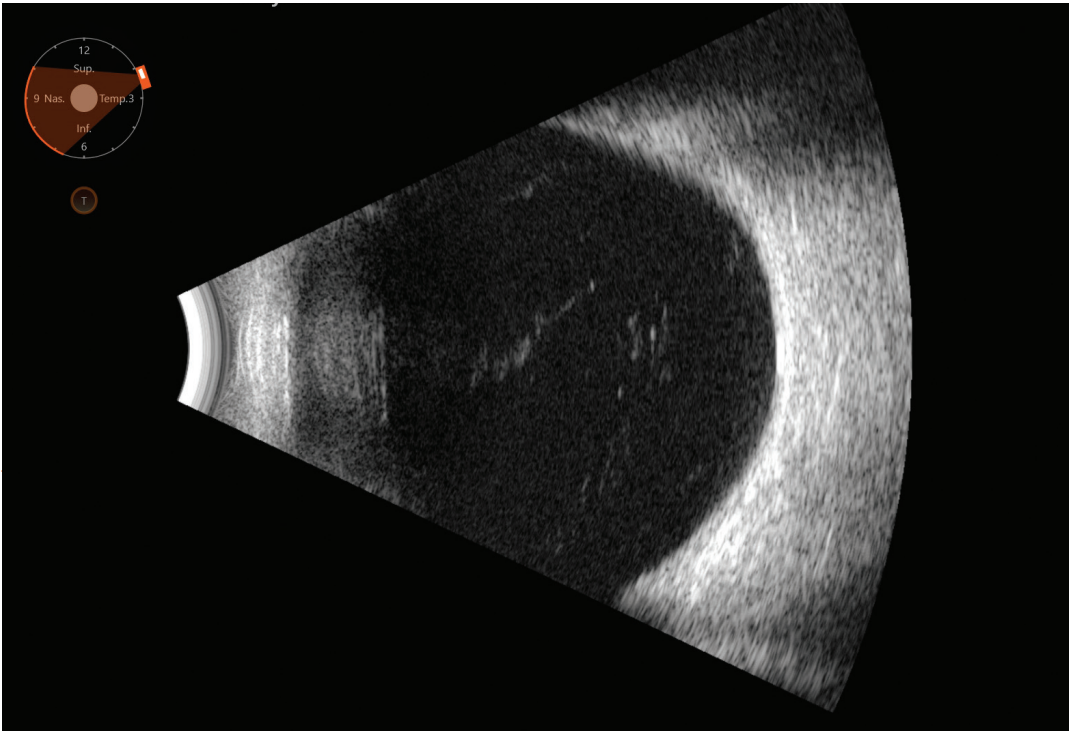
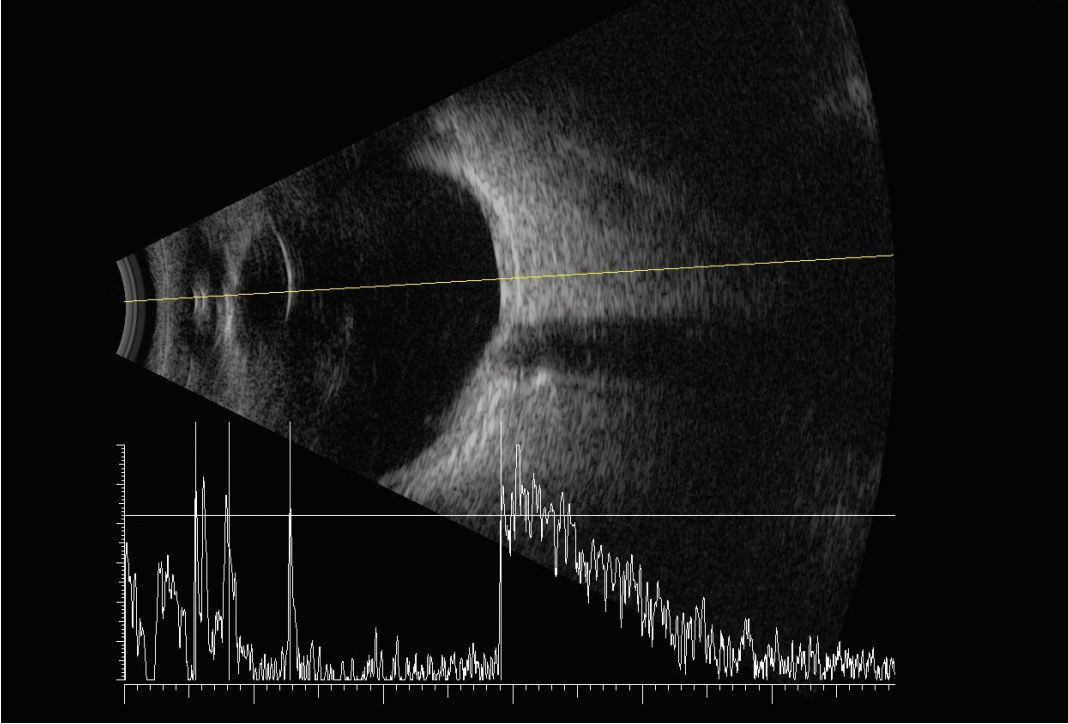


Fig 46: Weiss ring at 10 MHz resolution.

Fig 47: Weiss ring seen with 20 MHz resolution.

Note the improved detail of the Weiss ring which is detached tissue from the optic disc.

Fig 48: Vitreous cyst.

A rare vitreous anomaly.

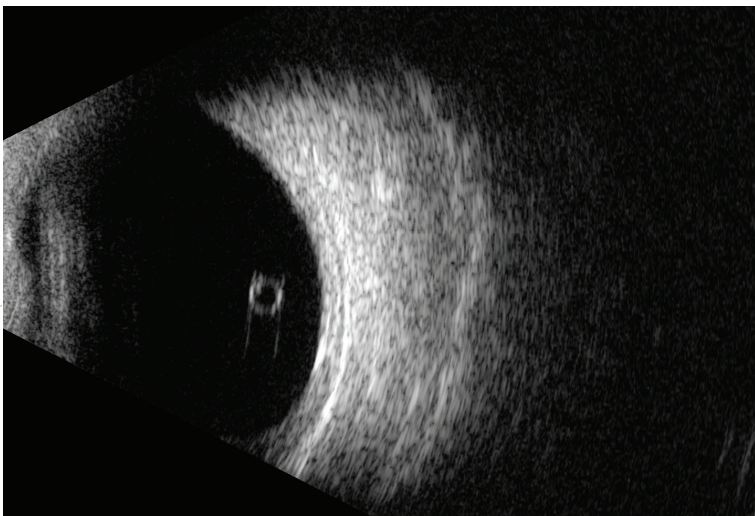
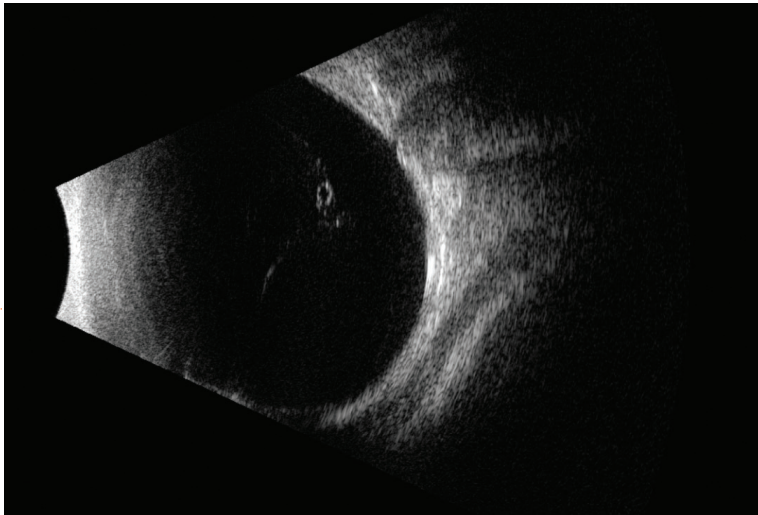
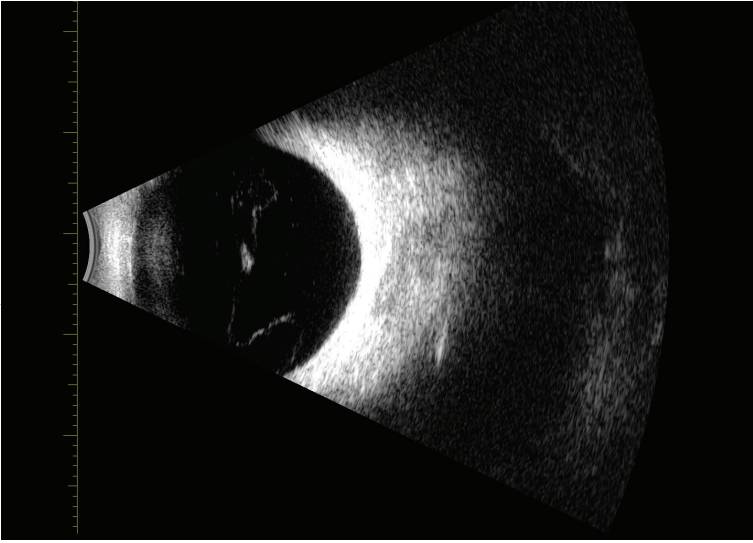


Fig 49: Subhyaloid hemorrhage in a diabetic patient with gliosis of the disc.

Gliosis is a common source of hemorrhage in diabetic patients.

Fig 50: Asteroid hyalosis with a shallow tractional retinal detachment.

Asteroid Hyalosis is deposits of cholesterol which are highly reflective on ultrasound but the patient usually retains good acuity.

Fig 51: Vitreous haex with lacunae.

These are cystic spaces within the vitreous.

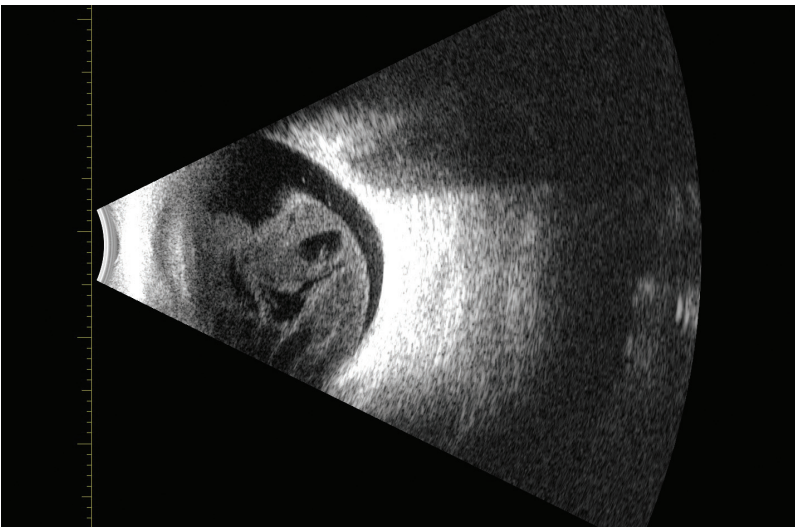
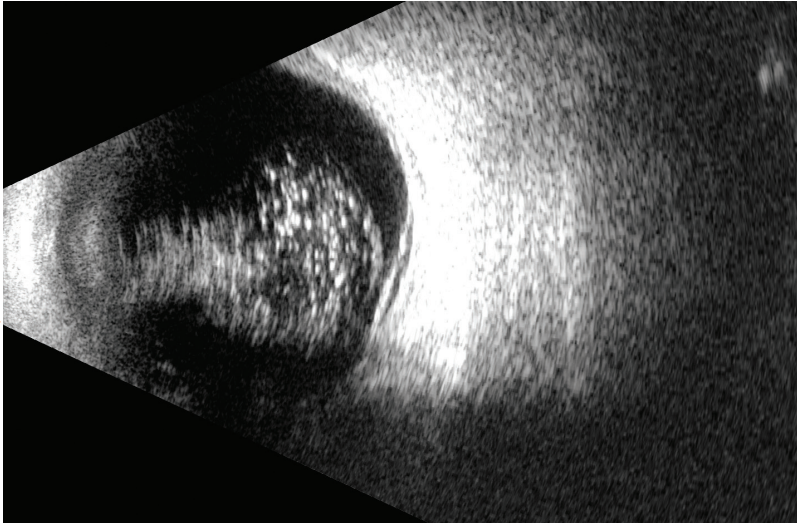
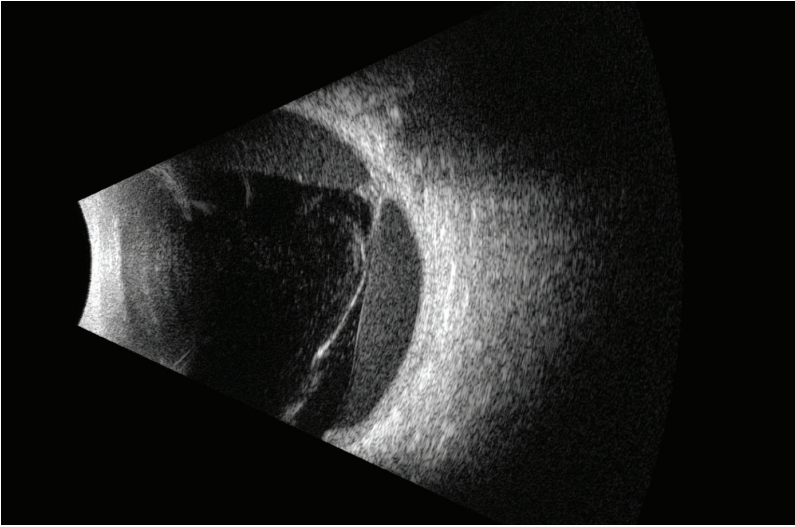


Fig 52: Intragel and subhyaloid hemorrhage.

Intragel hemorrhages can be diffuse, of variable reflectivity or show clumping of vitreous opacities. Subhyaloid hemorrhages are always diffuse.

Fig 53: Intragel hemorrhage and full PVD.

Fig 54: Intragel hemorrhage and a full PVD.

The posterior hyaloid membrane can be highly reflective and mistaken for a retinal detachment but lack of continuity and variable reflectivity is indicative of a PVD. Standardized A-scan is also of value as a retinal detachment will have a high scleral reflectivity.

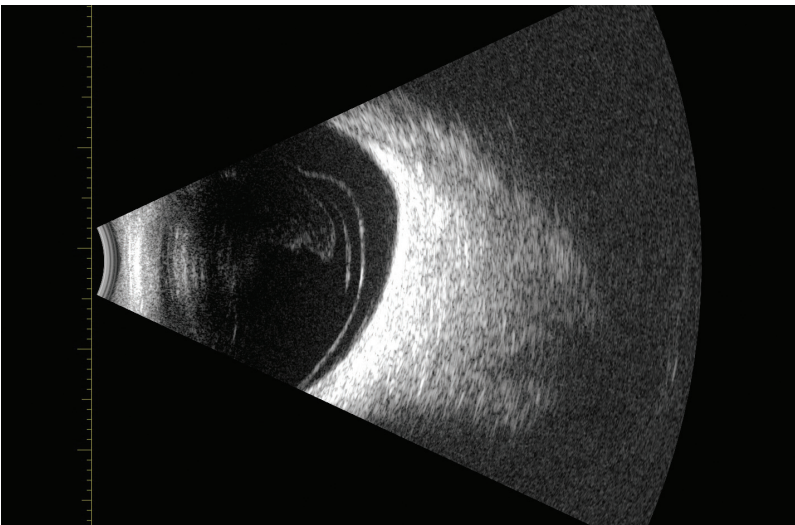
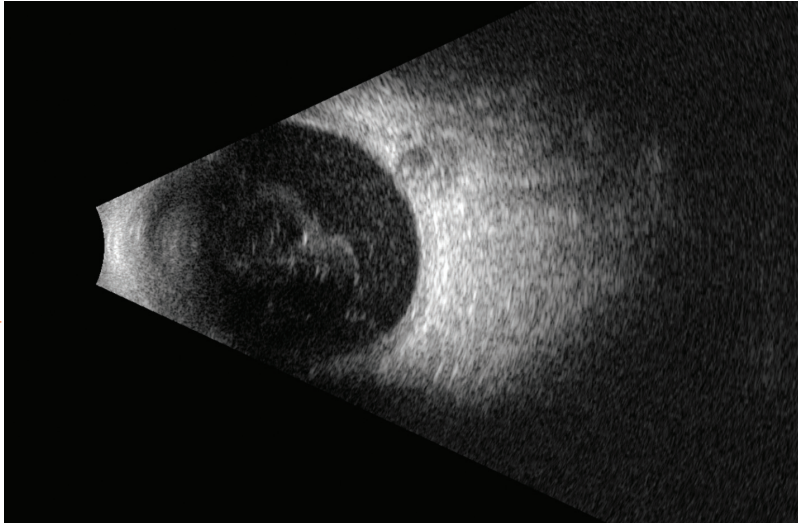
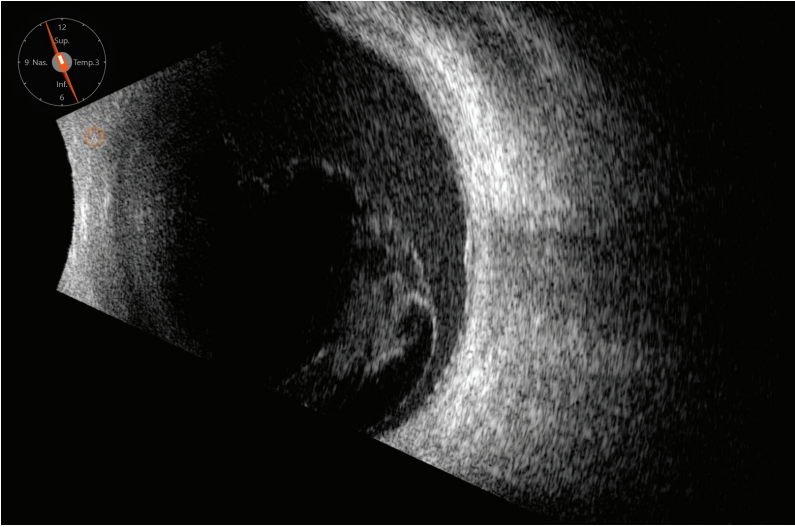


Fig 55: Blood in vitreous space showing diffuse blood cells with no vitreous membrane.

After a vitrectomy any blood in the vitreous space will be diffuse. Some vitreal remnants may also occur depending on the nature of the vitrectomy.

Fig 56: Breakthrough vitreous hemorrhage with a macular disciform CNVM lesion.

It is important to look for macular lesions in any case of spontaneous vitreous hemorrhage particularly in cases of AMD.

Fig 57: Blood clot adjacent to an old retinal tear.

Any blood clot exhibits hyperreflectivity.

Fig 58: Diabetic vitreous hemorrhage with vitreoretinal traction and tenting of the retina.

Diabetic vitreous hemorrhage is often associated with vitreo retinal traction and associated tractional retinal detachment. It is important to determine whether the macula is detached.

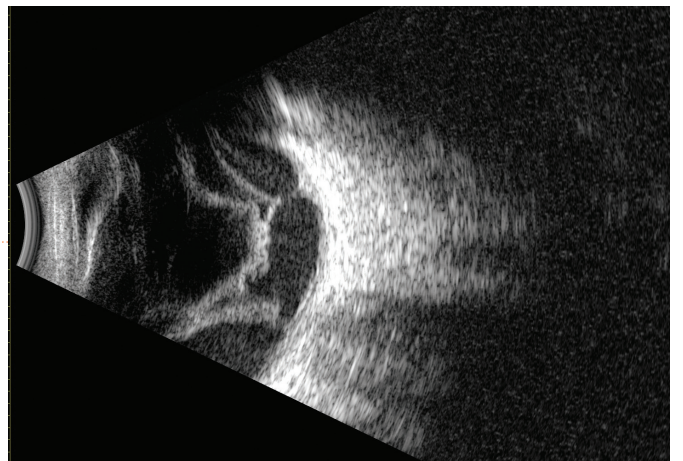
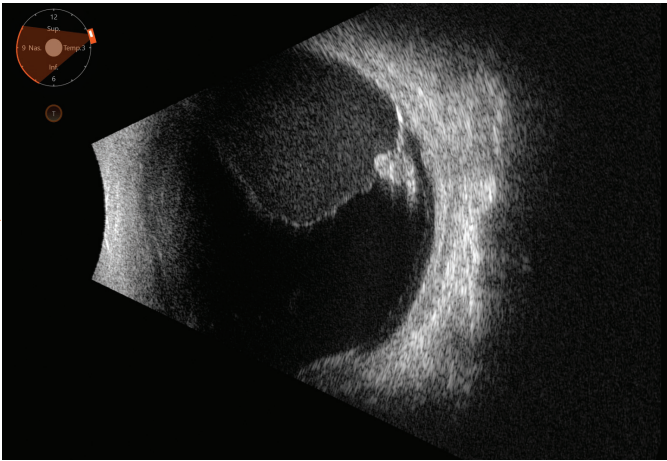
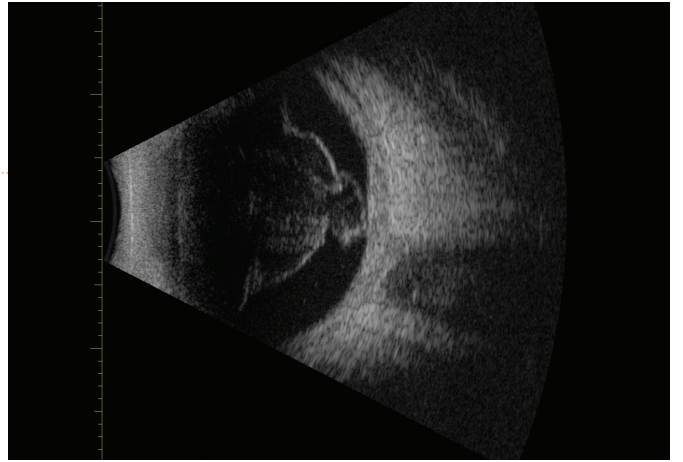
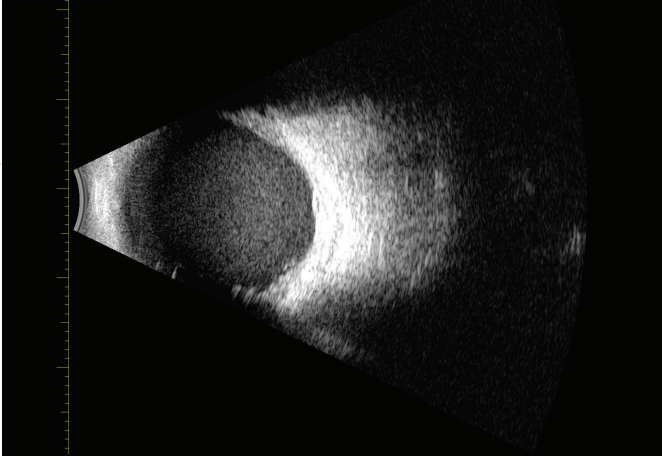


Fig 59.1: Dislocated lens nucleus and vitritis in a diabetic patient.

Dislocated lens nuclei are often seen in the inferior vitreous and are commonly associated with vitreous cells.

Fig 59.2: Non traumatic rupture of the posterior lens capsule in the same diabetic patient.

Part of the lens still remains.

Fig 60: Multiple areas of vitreo retinal traction in a diabetic vitreous hemorrhage.

Fig 61: Endogenous endophthalmitis with detached inner limited membrane.

One of the differentiating features of endophthalmitis is a detachment of the ILM. This is due to fluid building up within the intraretinal layers.

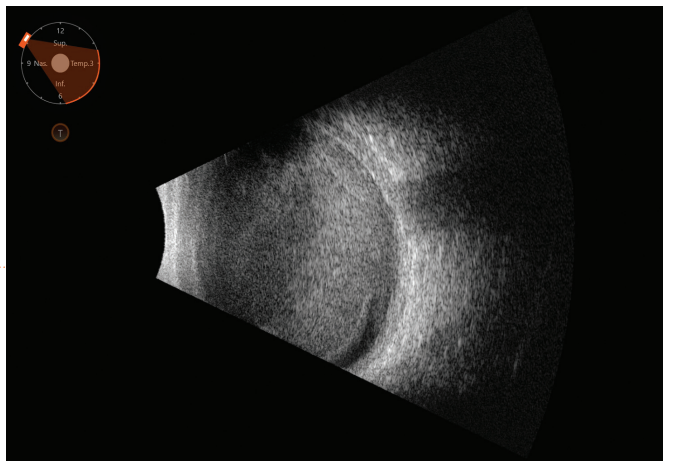
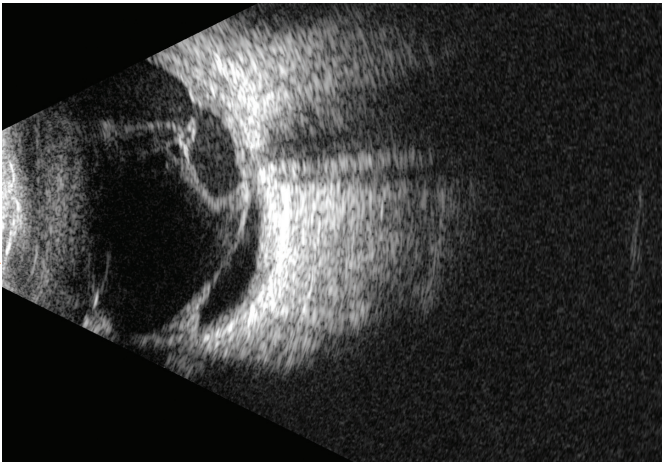
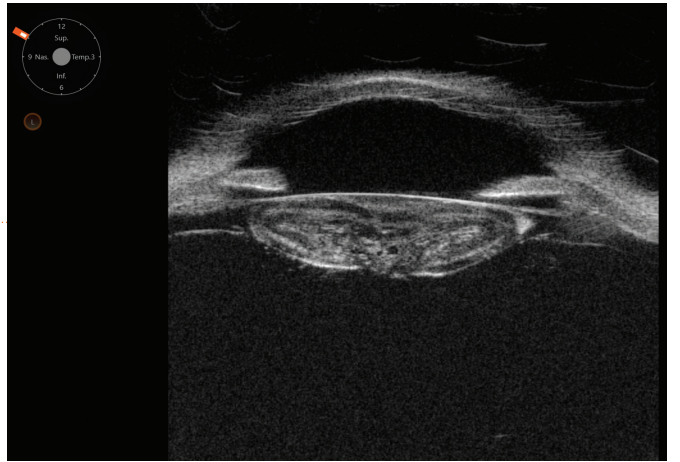
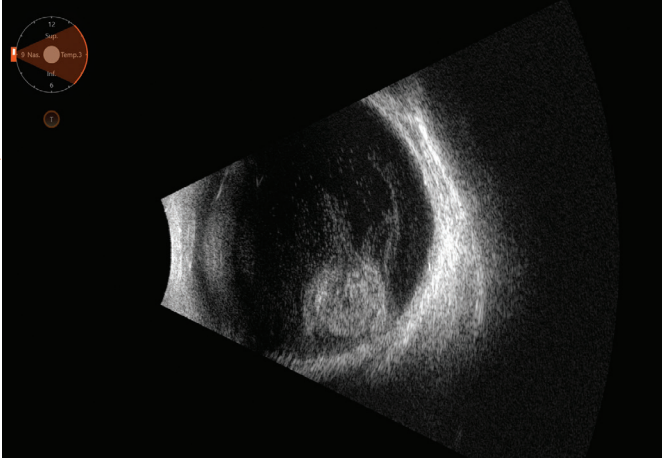


Fig 62.1: MHz image of papilloedema showing elevation of the retinal nerve fibre layer beyond the disc margin.

Ultrasound in disc oedema is used mainly to identify disc drusen. Diffuse thickening of the RNFL outside the disc area plus fluid distension of the nerve sheath are indicative of papilloedema.

Fig 62.2: Membrane from previous vitreous hemorrhage. This looks like a retinal detachment but there is no attachment to the choroid.

Fig 63: Vitreous cells in a patient with vitritis. The echoes are more uniform than with vitreous hemorrhage.

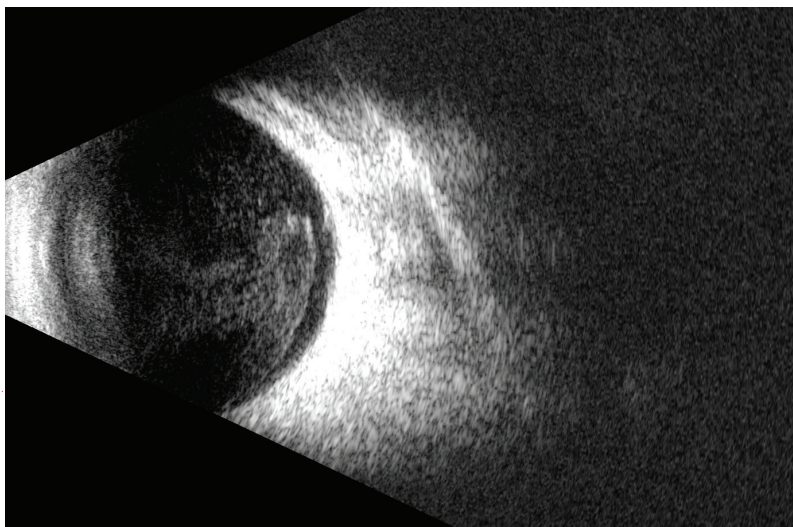
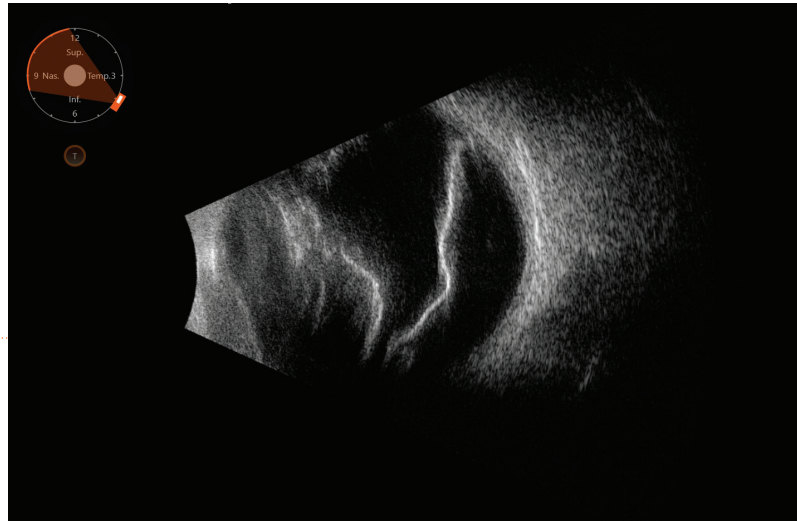
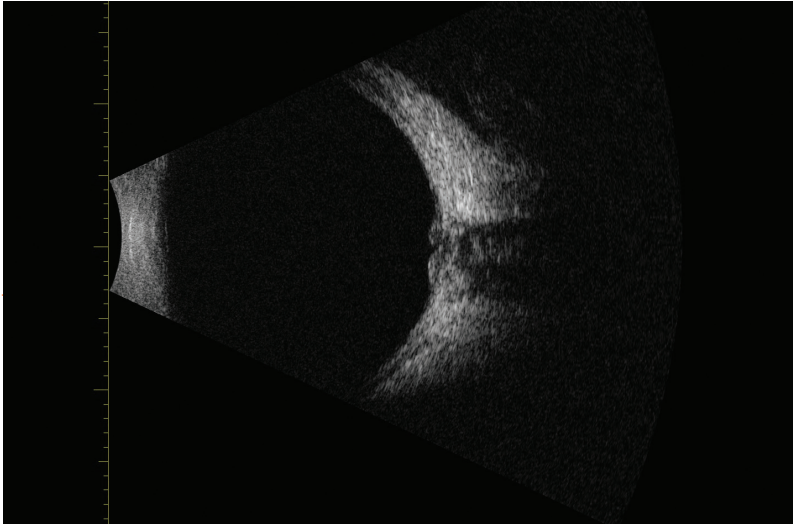


Fig 64: Patient with sticklers syndrome (collagen 11 disorder). The changes in the vitreous are due to changes in vitreous interfaces in an empty vitreous.

Fig 65: Intragel hemorrhage with a vitreous frond.

The most common association with vitreoretinal traction in the presence of a vitreous hemorrhage often results in a thickening of the hyaloid surface adjacent to the retina.

Fig 66.1 Vitreous frond 20 MHz probe.

With higher frequency imaging the lack of sub retinal fluid is easily identified.

Fig 66.2 Vitreous tag frond.

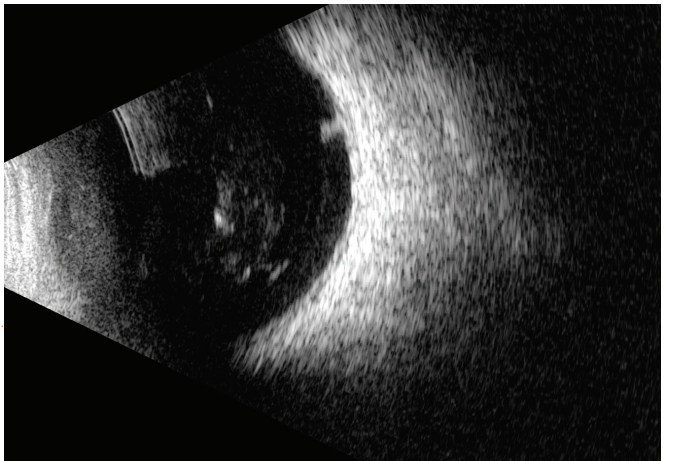
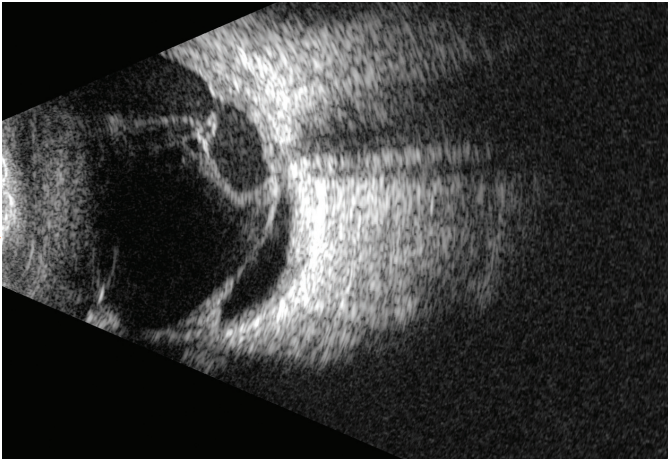
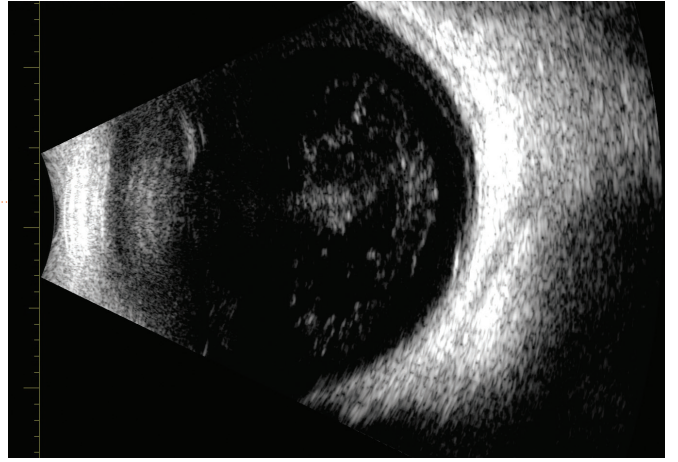
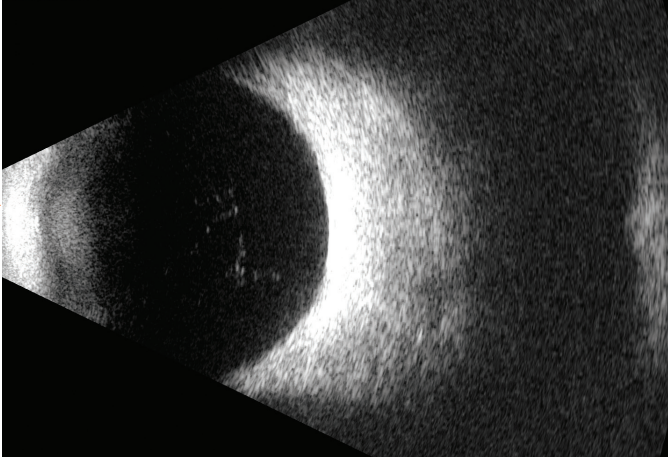


Fig 67: Preretinal fibrotic membrane. This can be differentiated from a retinal detachment by the variable reflectivity of the membrane.

Fig 68: Lasered retinal tear and vitreous hemorrhage showing no elevation of the adjacent retina.

When identifying retinal tears it is important to look for vitreoretinal attachment which is mostly superior between 10 and 2 o'clock. At the vitreoretinal attachment there may be fronds, treated tears, or fresh tears. Treated tears are characterised by the lack of a gap behind the preretinal or retinal membrane.

Fig 69: Lasered tear.

Fig 70: Retinal tear with vitreous hemorrhage showing vitreal traction. Note that the retina is elevated on both sides of the tear a characteristic feature.

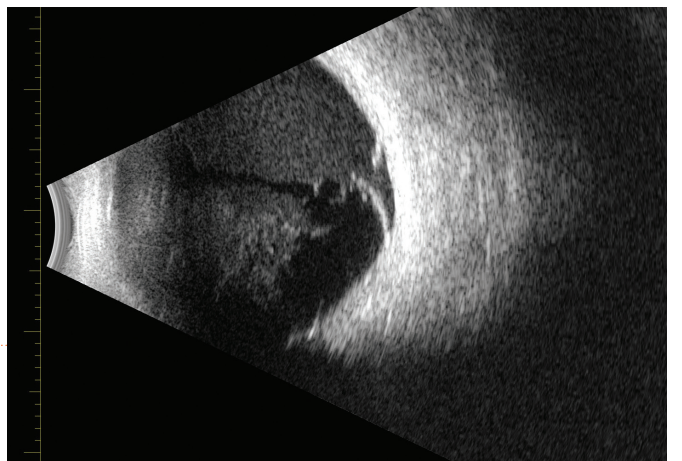
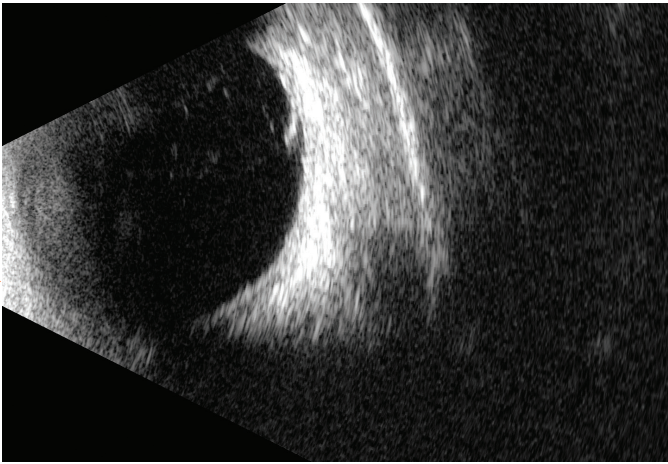
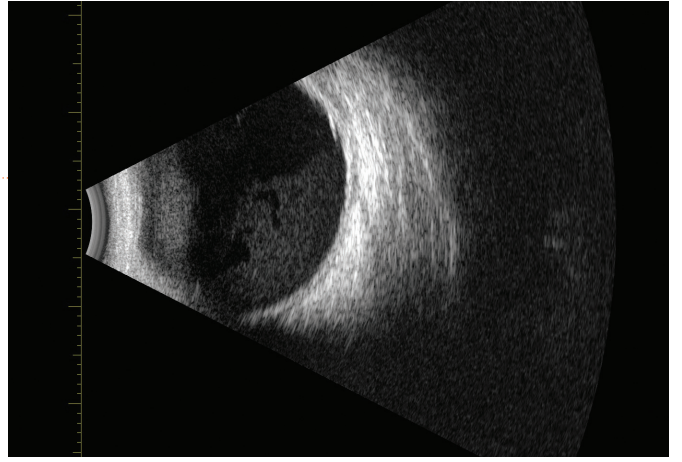
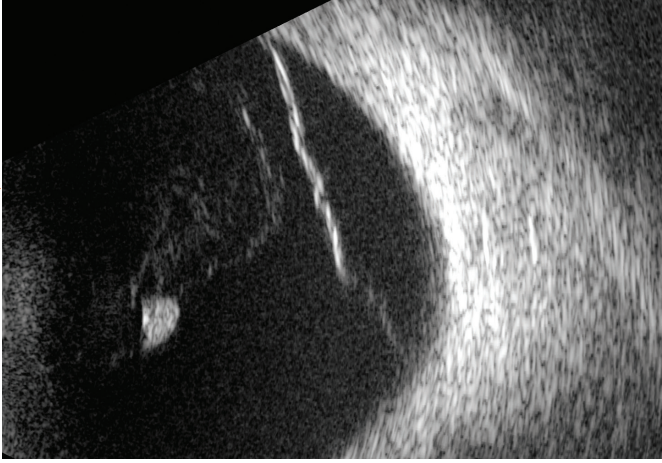


Fig 71.1: Operculum with a 10 MHz probe.

The retinal hole can be seen behind the operculum.

Fig 71.2: Operculum with a 20 MHz probe.

Fig 72: Small tear with adjacent sub retinal fluid and vitreous traction.

Fig 73: Large retinal hole with operculum.

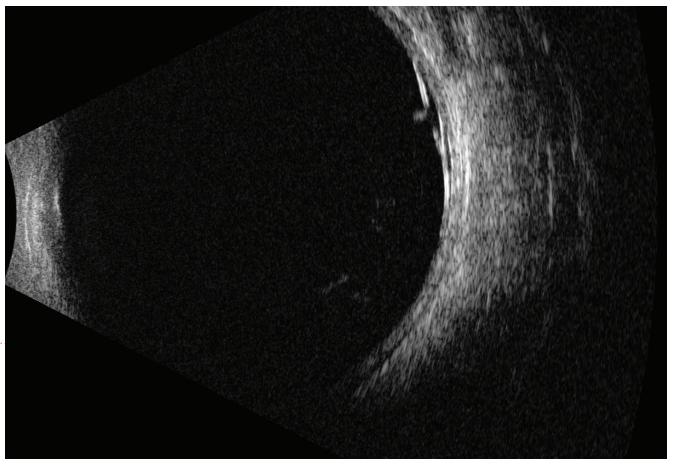
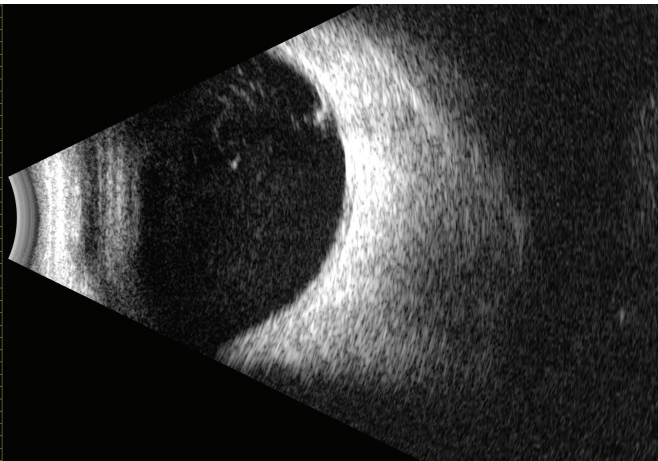
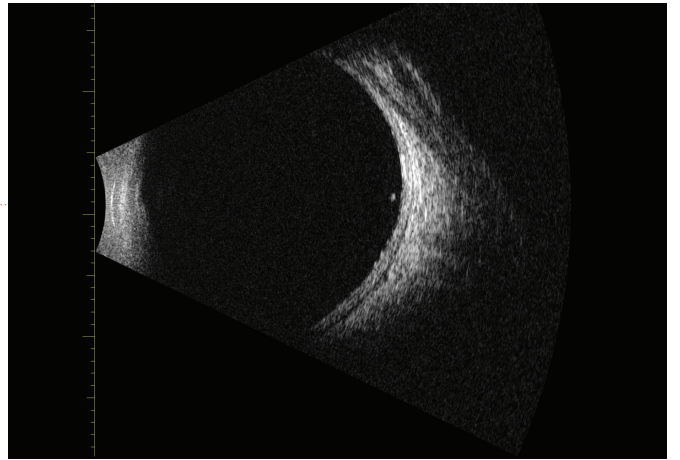
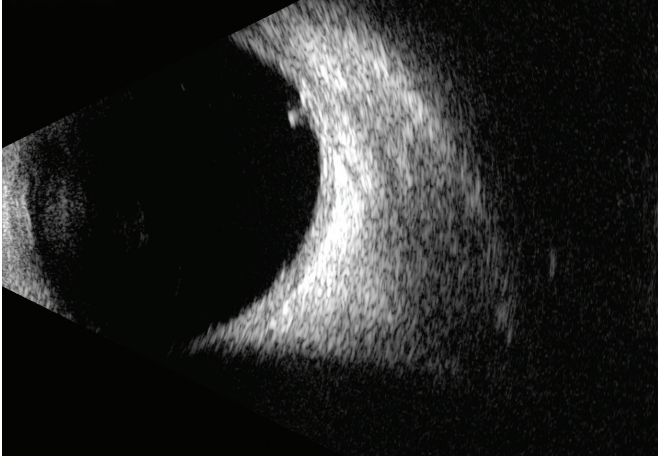


Fig 74: Giant retinal tear showing folded retina.

Giant retinal tears are characterised by multiple folded layers of highly reflective membranes. Small tears are characterised.

Fig 75: Giant retinal tear.

Fig 76: Inner leaf split adjacent to a retinoschisis the value of 20 MHz imaging.

Is seen where the inner and outer leaf split can be seen peripherally.

Fig 77: Inner and outer leaf detachment seen on UBM, B-scan and indented funduscopy suggested retinoschisis only.

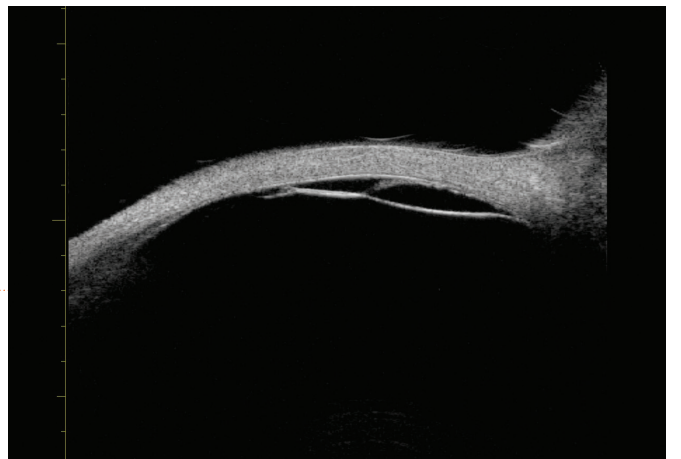
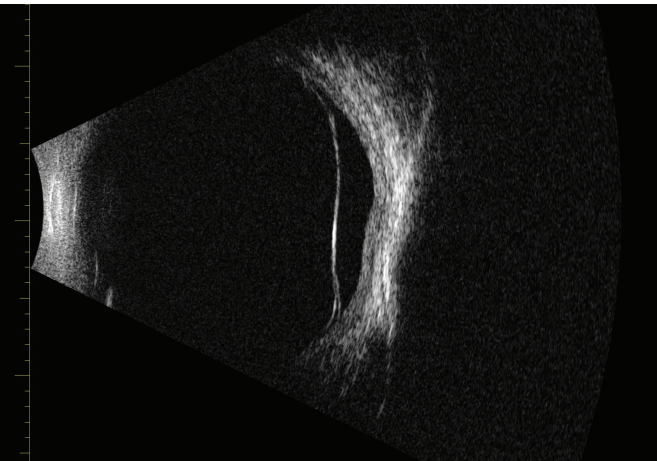
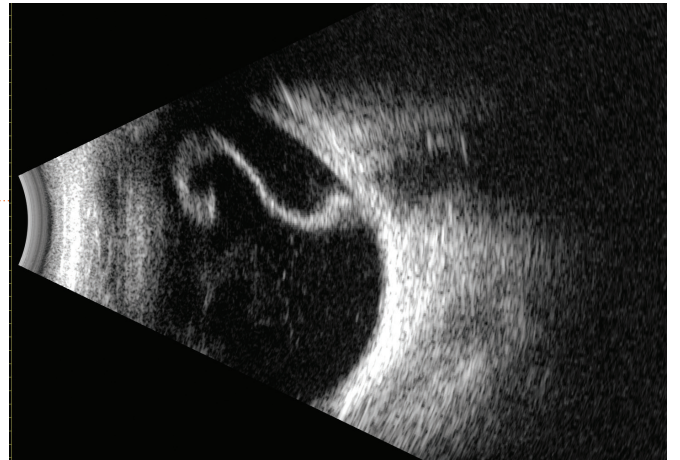
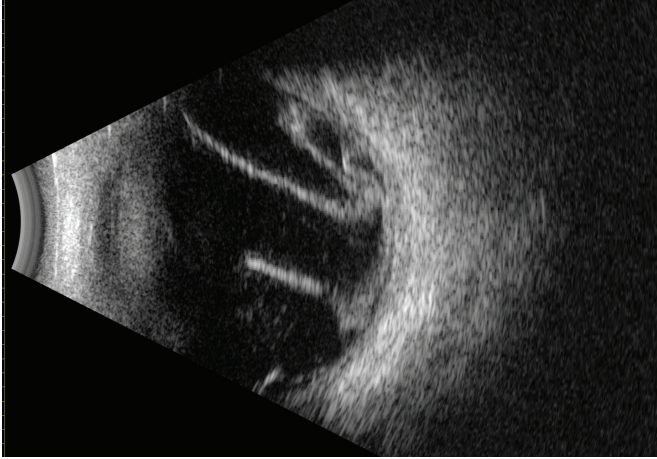


Fig 78: Full thickness retinal detachment.

Fig 79: Large retinal tear.

Fig 80: Funnel shaped retinal detachment with attachment either side of the optic disc not in front of the disc as in a partial PVD.

The characteristics of retinal detachments are

- a) uniform reflectivity,
- b) funnel shape,
- c) less mobility,
- d) attachment adjacent to but not in front of the disc.

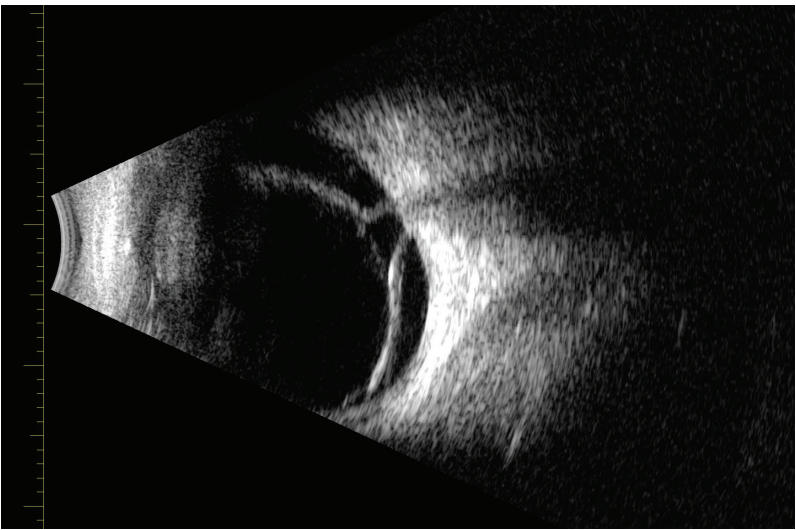
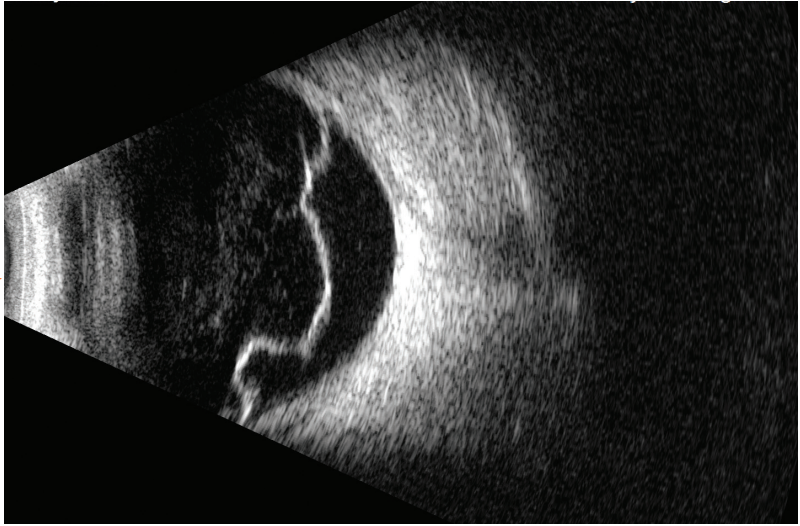
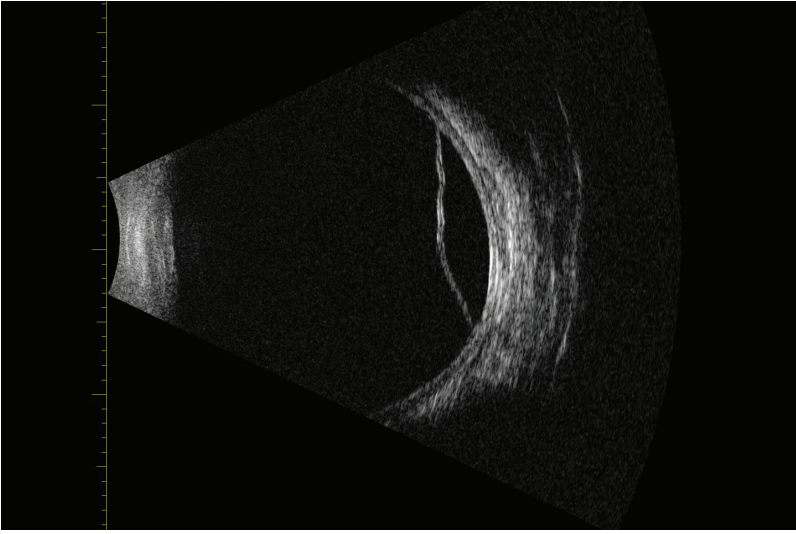


Fig 81: Rhegmatogenous retinal detachment with retinal folds.

Folds in the membrane are an indication of a retinal detachment with PVR not normally seen in a PVD.

Fig 82: Intraretinal cyst in a localised retinal detachment.

Fig 83: Shallow retinal detachment in a high myope detected by 20 MHz.

Fig 84: Exudative retinal detachment in association with an effusive choroidal detachment.

Choroidal effusion and retinal effusion are often seen in combination.

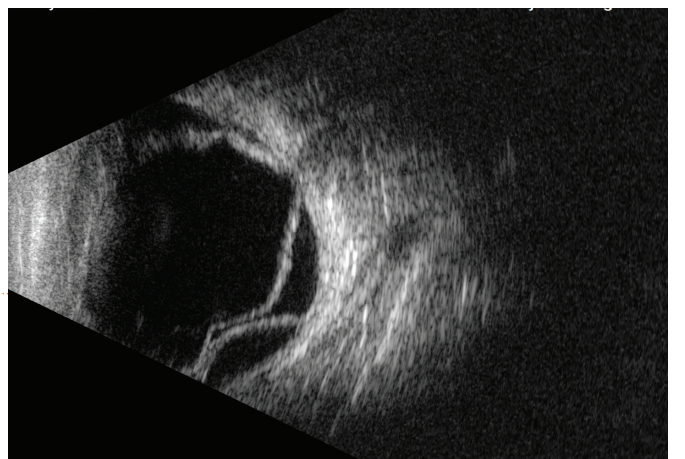
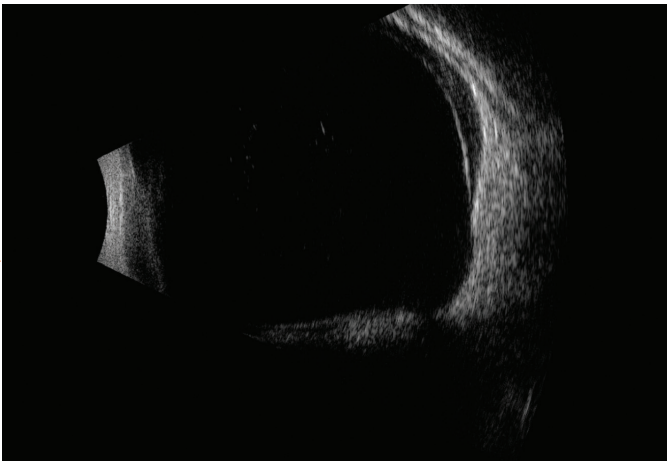
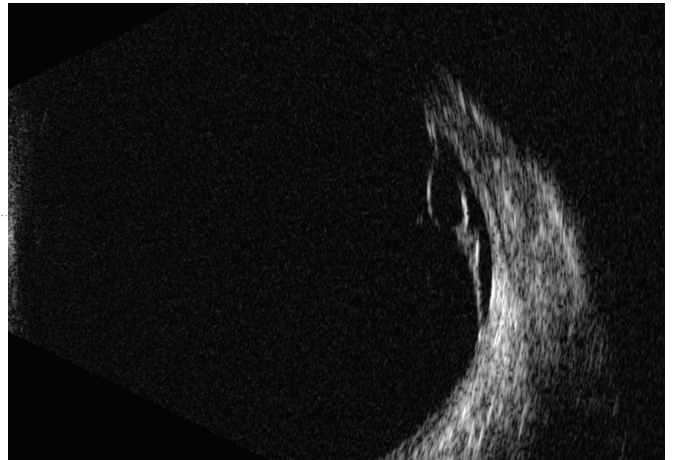
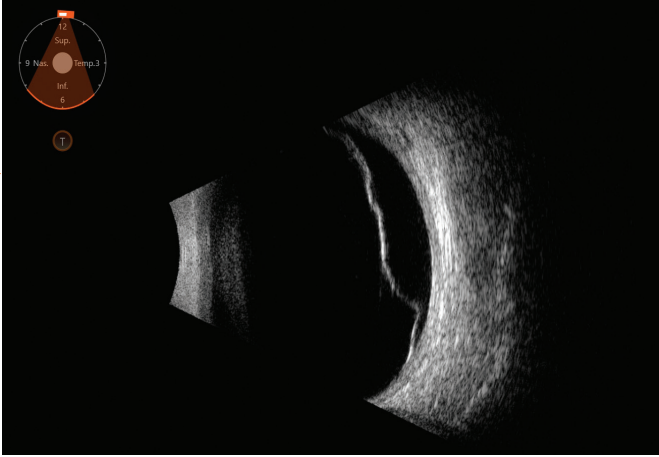


Fig 85: Suprachoroidal hemorrhage.

Occurs frequently after surgery or trauma particularly if the patient is taking blood thinners such as Warfarin. They differ from choroidal effusion by the presence of hyperreflective echoes behind the choroid.

Fig 86: Coats disease showing a total funnel retinal detachment with sub retinal cholesterol and intra retinal exudate.

Fig 87: Encircling choroidal detachment in choroidal effusion.

Fig 88: Suprachoroidal hemorrhage in a vitrectomised eye with blood in the vitreous space. The patient was taking warfarin.

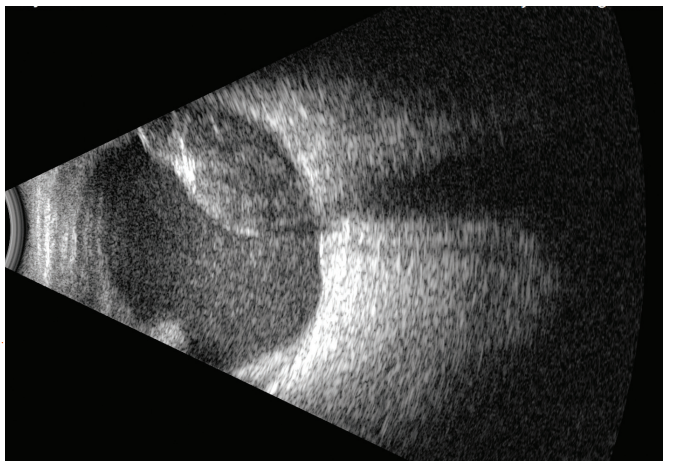
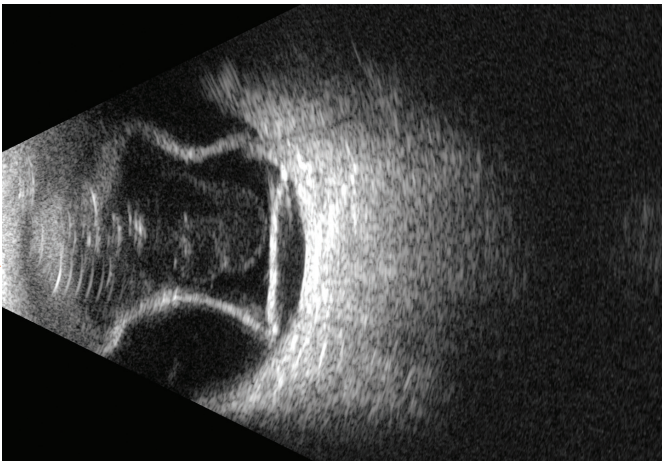
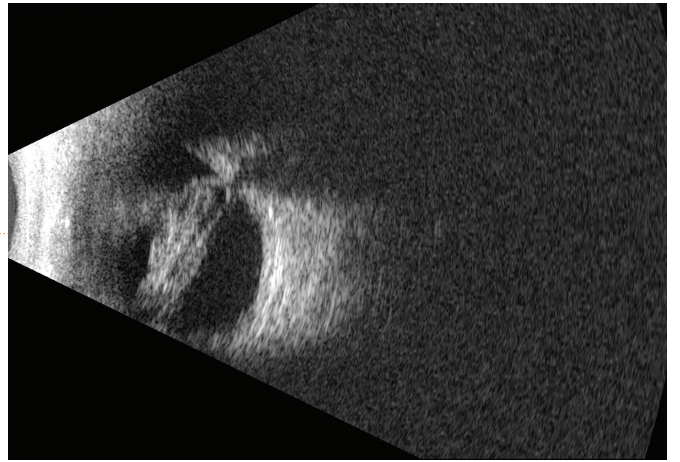
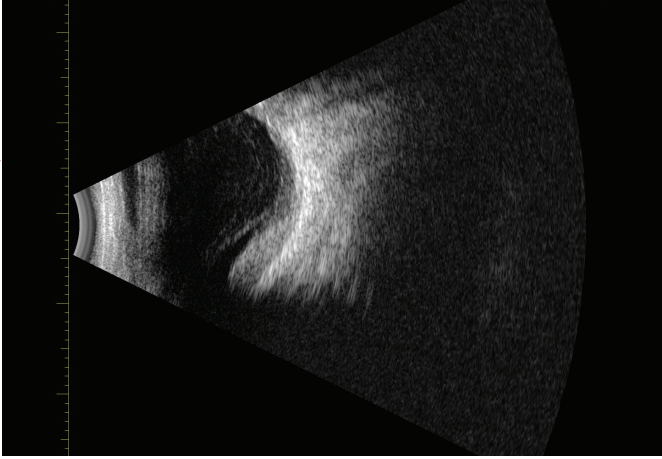
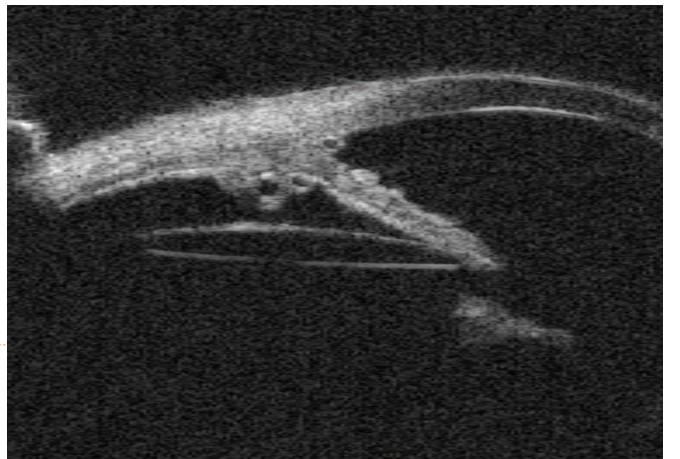
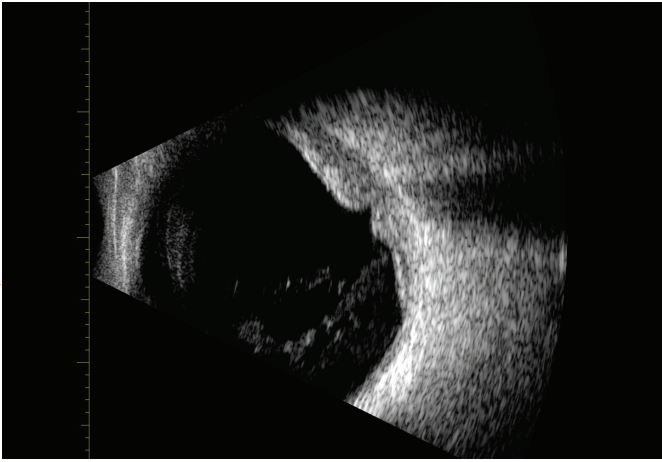
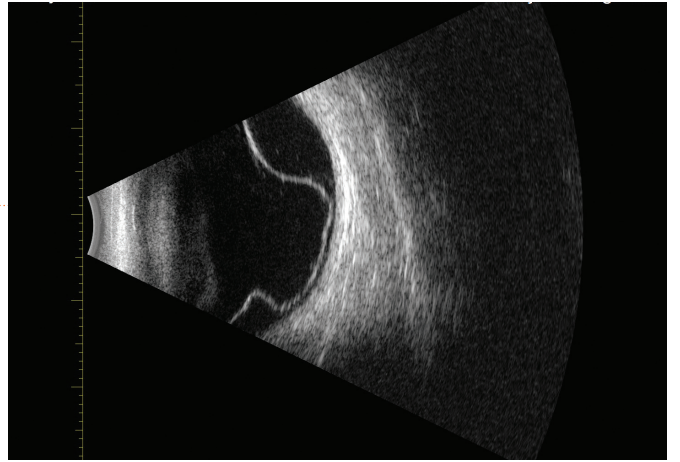
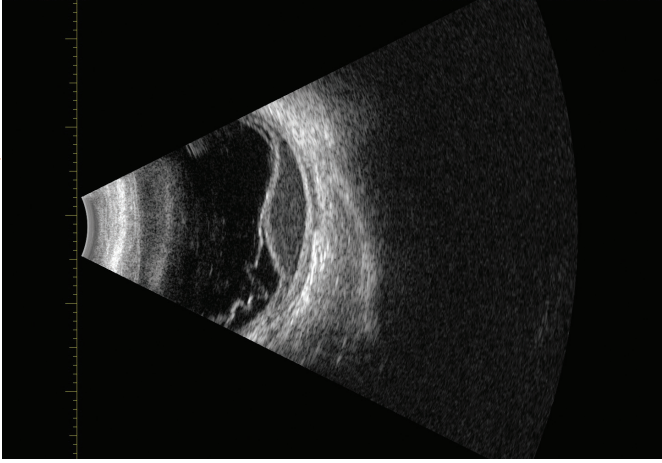


Fig 89: Uveal effusion syndrome with choroidal and retinal effusion.

Fig 90: Uveal effusion after steroid treatment.

Fig 91: Sub retinal hemorrhage in age related macular degeneration. Note the high reflectivity of a CNVM .

Fig 92: Dislocated IOL adjacent to the ciliary body at 6 o'clock.



ULTRASOUND OF THE VITREOUS AND RETINA.

Ultrasound examination of vitreo-retinal abnormalities is the most common use of ocular ultrasound but can be the most difficult to interpret. Most probes used for this examination are of 10 MHz frequency but 15 MHz probes can give higher resolution.

The globe can be scanned through the eye lid or directly on the sclera. The advantages of scanning directly onto the sclera is that there is no sound attenuation and the location of the scan is more accurate due to the absence of a Bell's phenomenon. However, care must be taken to avoid corneal abrasion and direct contact with the sclera should be avoided in cases of trauma, infection, hypotony, or in scleritis.

The technique of scanning the globe in the case of opaque media involves scanning the globe from the temporal to nasal canthus with the probe (marker) held vertically. This is followed by scanning the globe from the superior to inferior orbital margin with the marker held horizontally. This form of scanning is termed transverse or limbus parallel scanning. This method scans 96% of the globe. If an abnormality is found (e.g. retinal tear) the patient should be instructed to look towards the abnormality and the probe held opposite the abnormality with the marker pointing towards the abnormality. This is termed longitudinal scanning and ensures that the abnormality is perpendicular to the abnormality. Perpendicularity is important in order to measure the dimensions of any abnormality.

If membranes are detected within the vitreous cavity it is important to determine whether these represent a vitreous detachment (PVD) or a retinal or choroidal detachment. There are several features to look for: A membrane attached either side of the optic disc of high and continuous reflectivity is likely to be a retinal detachment. A membrane attached at or in front of the optic disc and of variable reflectivity is most likely a posterior vitreous detachment. A highly reflective membrane close to scleral reflectivity (identified by cross vector or standardized A-scan) is more likely to be a retinal detachment. Kinetic imaging is most important in differentiating between Vitreous and retinal detachment. PVD is usually more mobile than a retinal detachment. The presence of folds is more typical of a retinal detachment.

In diabetic patients the findings are often very complex and in the presence of vitreous hemorrhage multiple membranes may occur. Retinal detachments can be detected by looking for vitreous traction and a "tented" elevation of the retina. The vitreous is often immobile in diabetic hemorrhages.

Retinoschisis is identified by being dome shaped and typically peripheral. They are generally echographically thin with variable reflectivity and mostly immobile although some mobility is frequently seen. They are rarely attached to the disc.

Choroidal detachments are characterised by being dome shaped, usually peripheral, and immobile. They have double peaks on A-scan (cross vector) due to there being combined retinal and choroidal reflections.

It is possible to use ultrasound to differentiate types of vitreous opacity. Syneresis is characterised by low reflective variable opacities. In a full PVD the vitreous is fully mobile. Vitreous hemorrhages characterised by highly reflective echoes adjacent to a PVD. There is variability in reflectivity with signs of clumping of blood cells. Subhyaloid hemorrhages are diffuse. After a vitrectomy blood in the vitreous space is always diffuse. Inflammatory vitreal cells (vitritis) are diffuse and of low reflectivity. endophthalmitis is characterised by high density diffuse cells with minimal PVD. The density of the cells will increase a few hours after first presentation and this is an important diagnostic feature. The presence of fibrin can also be detected in the vitreous of endophthalmitis patients.

Fig 93: Norries syndrome showing microphthalmia and retinal folds.

Fig 94: Scleral folds in eye trauma with scleral perforation. This image was taken within 24 hours of the trauma before scleral repair. Despite the collapsed globe the patient recovered normal vision.

Within 24 hours of the trauma in the presence of scleral perforation the globe may collapse and ultrasound is of little value.

Fig 95: Large metallic foreign body (FB) showing an acoustic shadow and a vitreous hemorrhage.

Ultrasound is of great value in identifying the location of a FB. Only metallic FB can be detected.

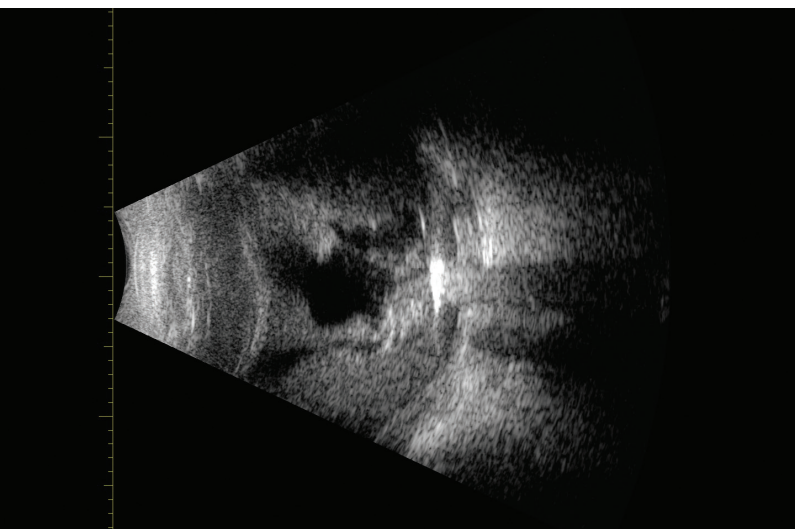
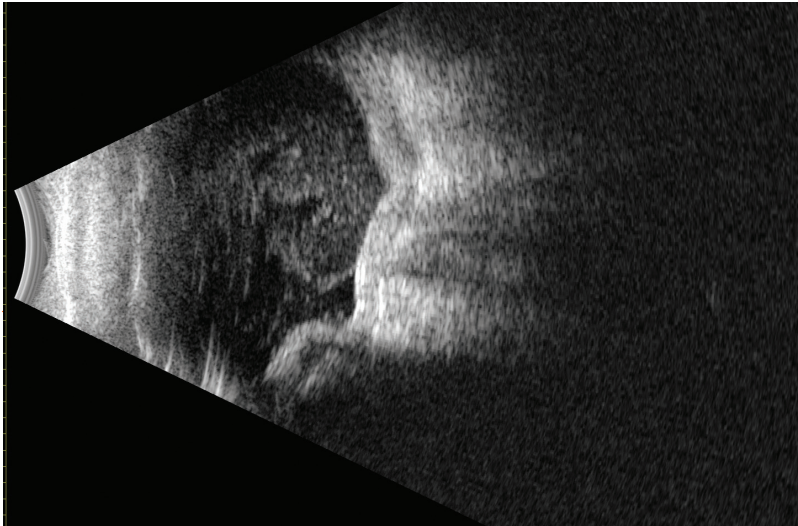
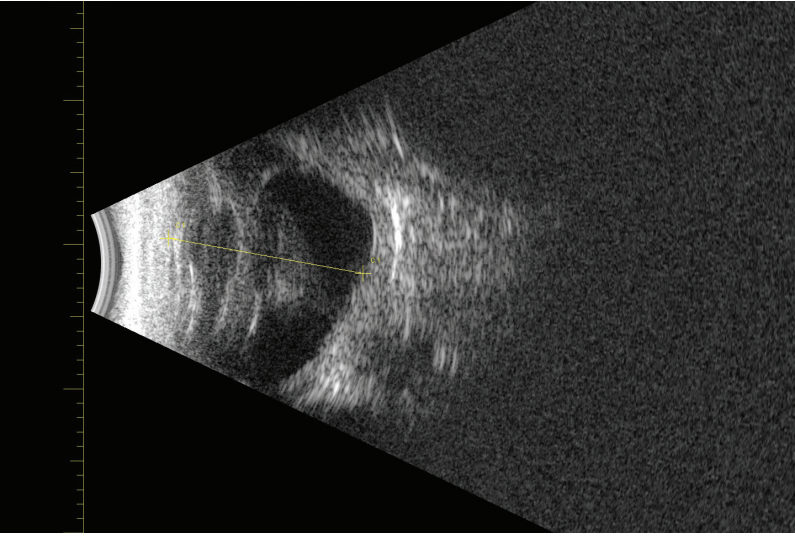


Fig 96: Annular 20 MHz probe image of vitreous incarceration with a track of a nail having penetrated, the globe anteriorly and exited into Tenon's space. Note hemorrhage in Tenon's space and the perforation through the sclera 1.

Fig 97: Same patient 2 weeks later showing a reduction in the extent of the suprachoroidal hemorrhage and natural healing of the scleral perforation.

Fig 98: PVD and triancimalone artefact.

Fig 99: Metallic IOFB with acoustic shadow. There is also a localised suprachoroidal hemorrhage.

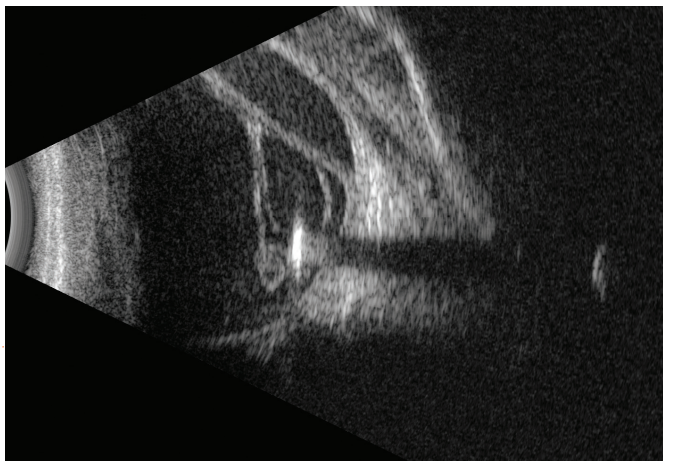
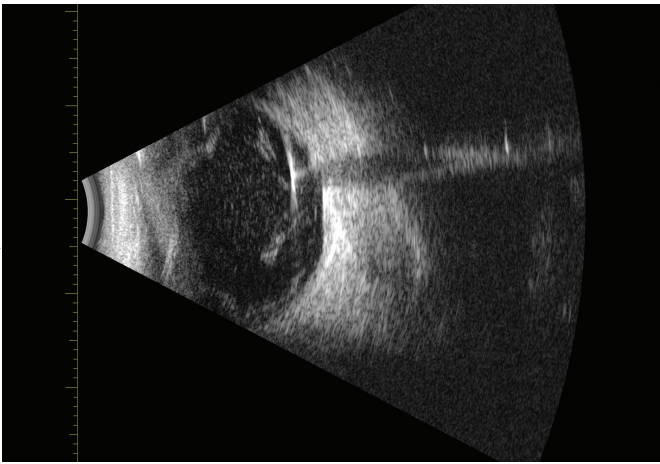
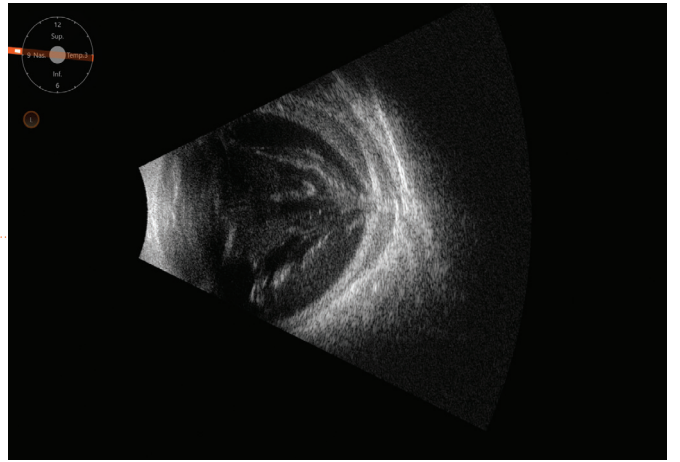
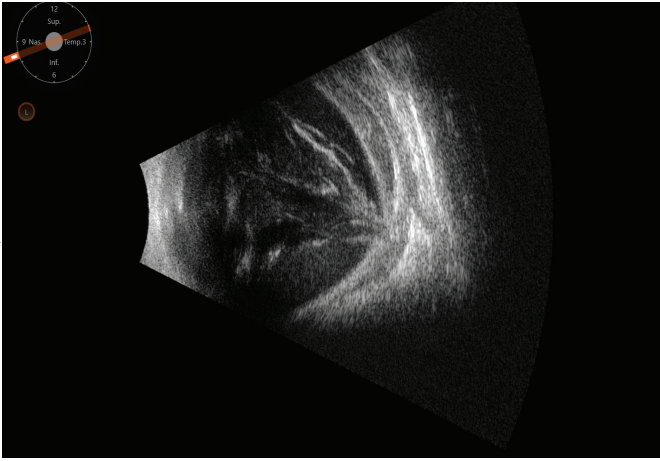


Fig 100: Optic disc coloboma showing deep retinochoroidal excavation.

Fig 101: Optic disc coloboma showing pre retinal membrane.

Fig 102: Deep optic disc coloboma with optic nerve cyst.

Coloboma are associated with pre retinal membranes and optic nerve retrobulbar cysts are common.

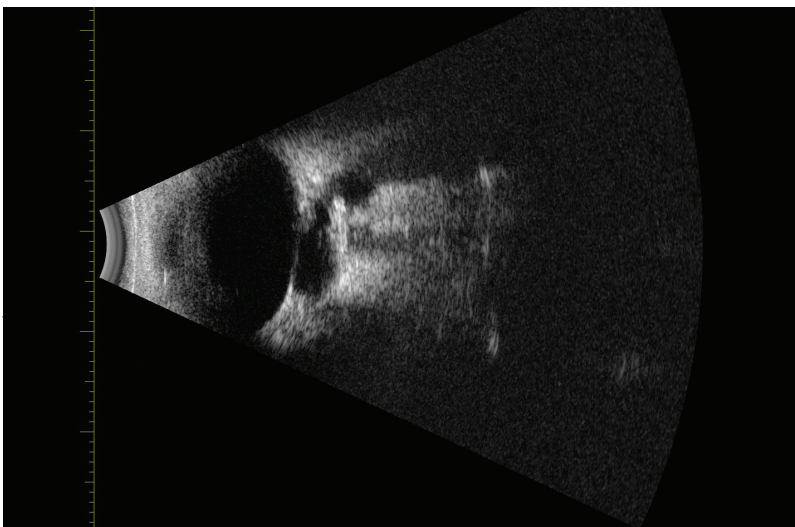
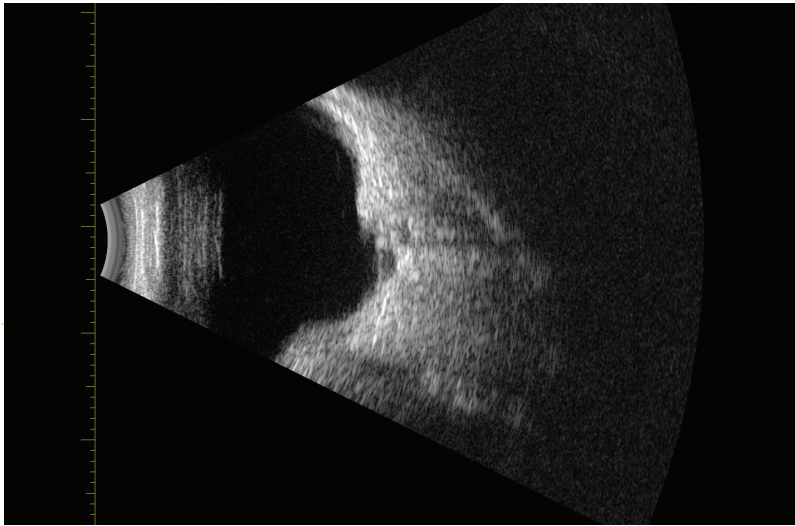
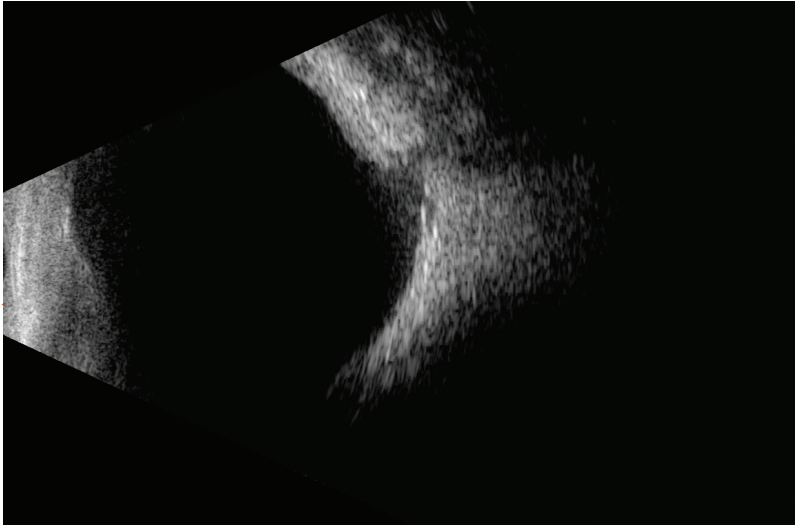


Fig 103.1: Cross sectional B-scan image of the optic nerve in a normal eye.

By holding the probe vertically (transverse image) at the lateral canthus and pointing towards the orbital apex nasally this cross sectional image can be obtained.

Fig 103.2: Deeply cupped disc in glaucoma using a 20 MHz probe.

Fig 104: Same patient showing atrophy of the optic nerve.

Fig 105: Diffuse distension of the optic nerve in acute optic neuritis.

Unlike disc oedema where the nerve sheath is distended the whole nerve is distended in optic neuritis during the acute phase.

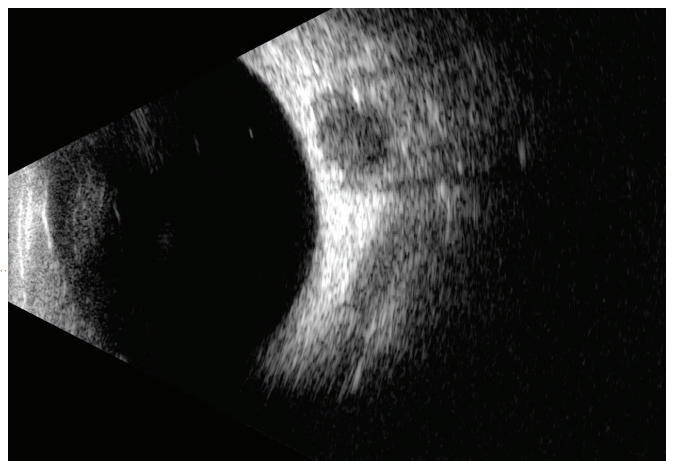
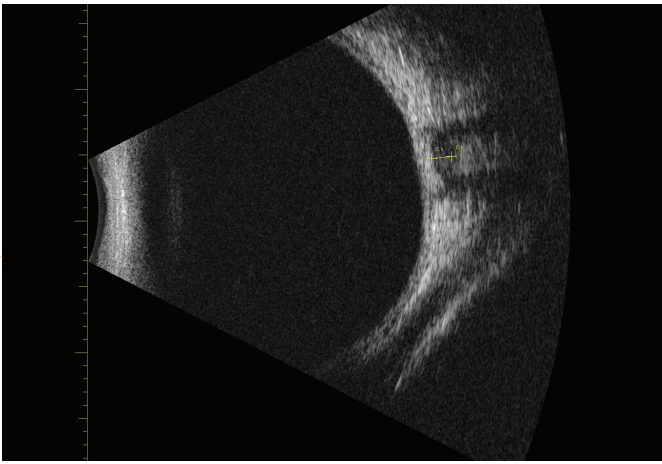
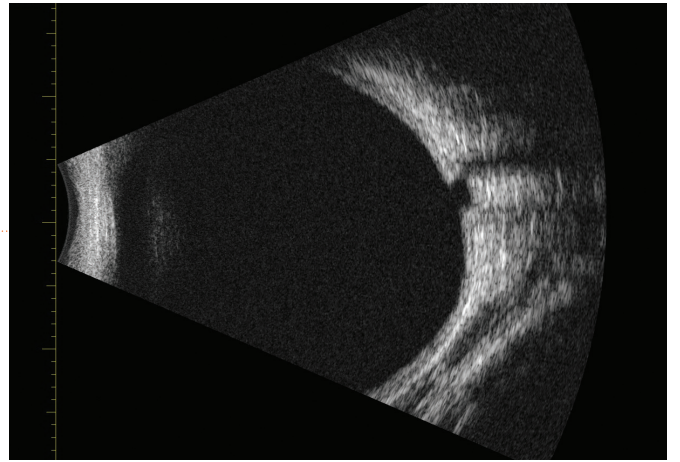
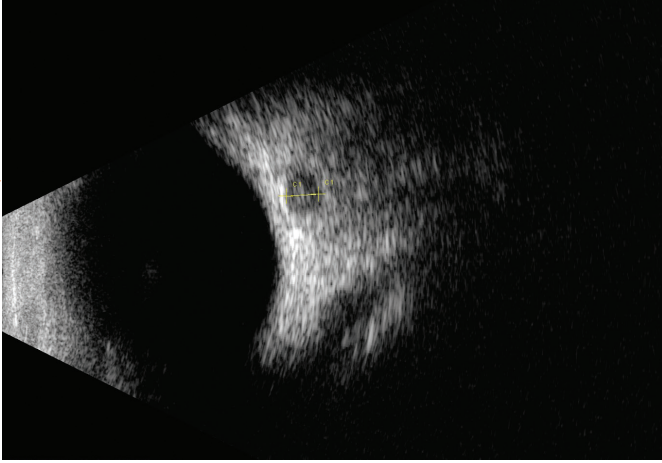


Fig 106: Fluid distension of the optic nerve sheath in papilloedema.

Fig 107: Combination of papilloedema and drusen, note that the elevated disc margin extends beyond the normal edge of the disc.

Fig 108: Buried optic disc drusen with a 20 MHz probe.

Calcified areas behind the surface of the disc are seen as hyperreflectivity. Reducing the gain will enhance these areas. In children the drusen is usually more superficial.

Fig 109: Buried optic disc drusen.

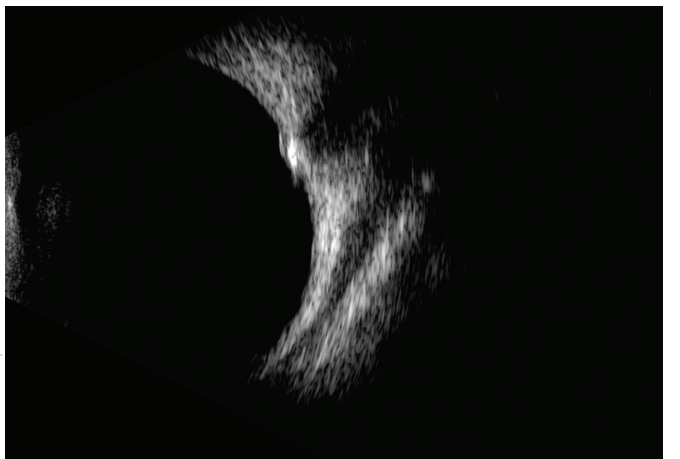
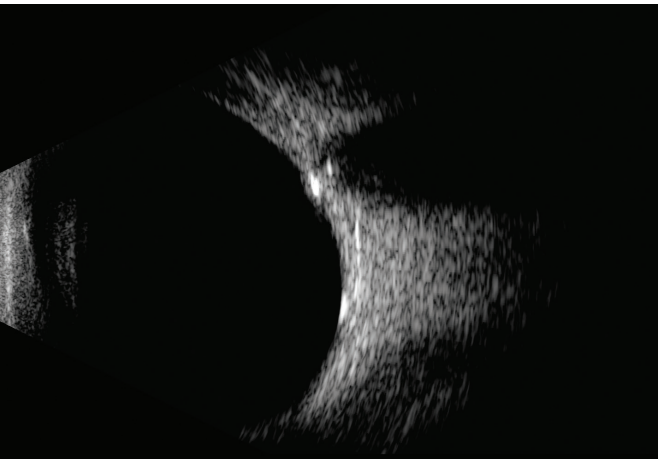
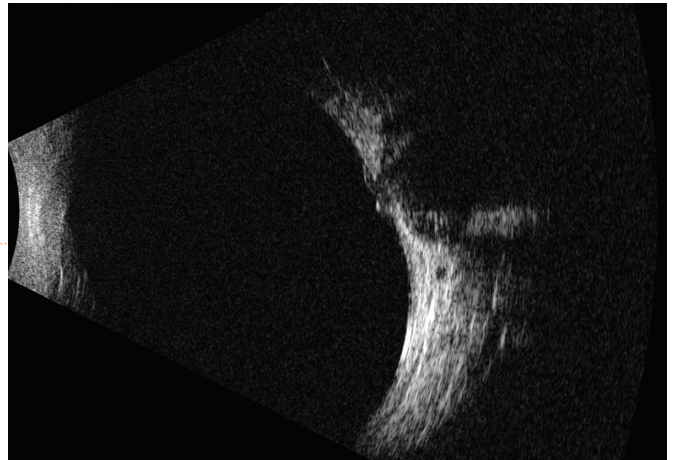
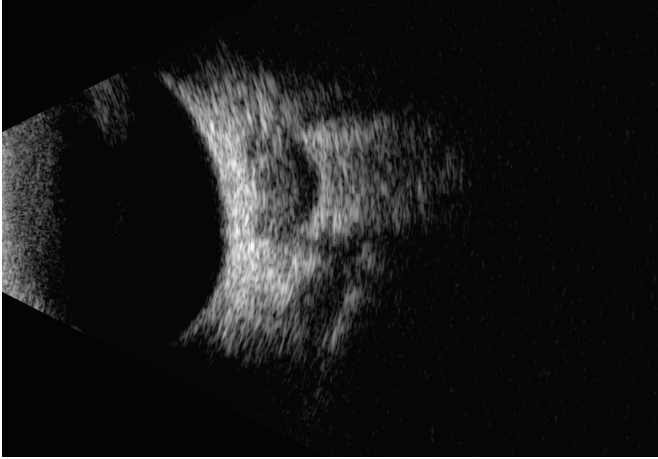


Fig 110: Unusual Disc drusen with 20 MHz probe.

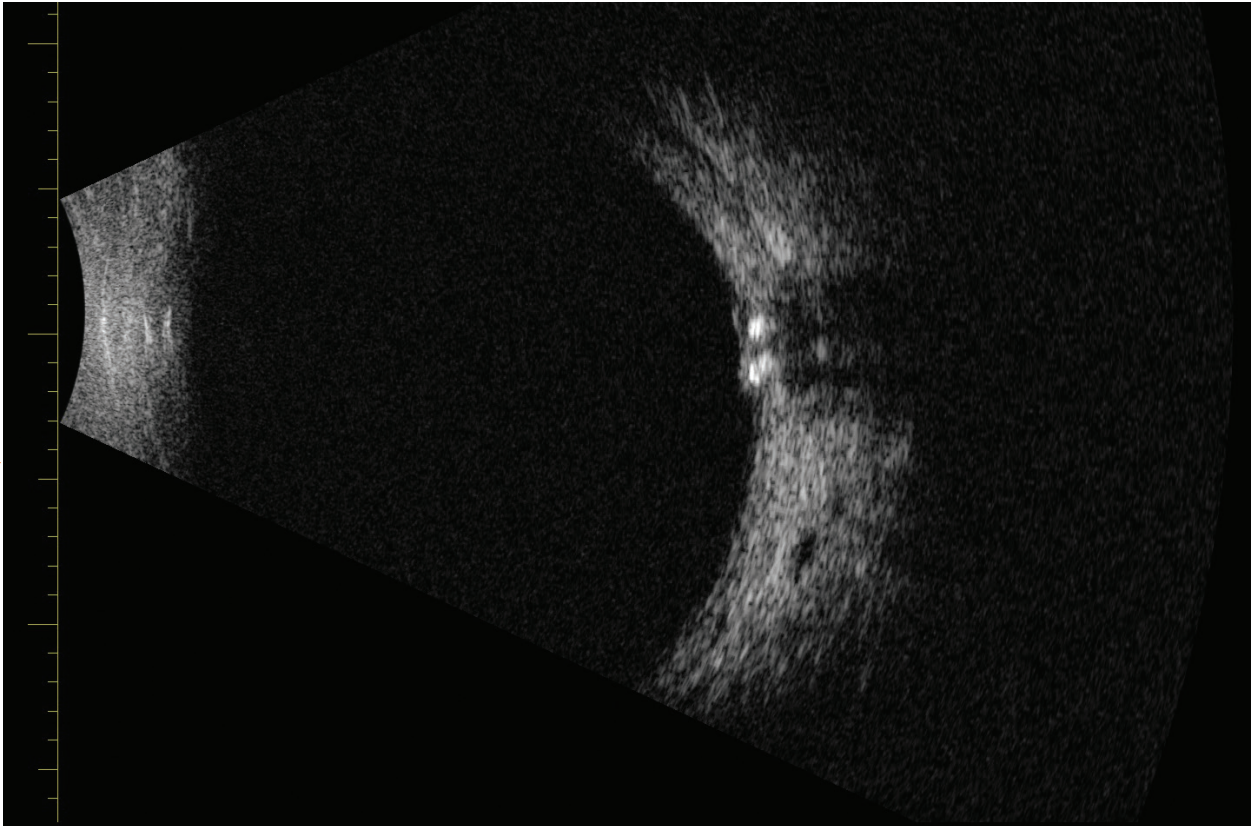


Fig 111: Disc swelling in aion. Note there is no fluid distension of the nerve sheath.

Fig 112: Melanocytoma of the optic disc. Note the difference compared to the buried disc drusen (less reflectivity, greater elevation).

Fig 113: Optic disc astrocytic hamartoma in a patient with tuberous sclerosis.

Fig 114: Optic disc angioma. Note dilated blood vessels.

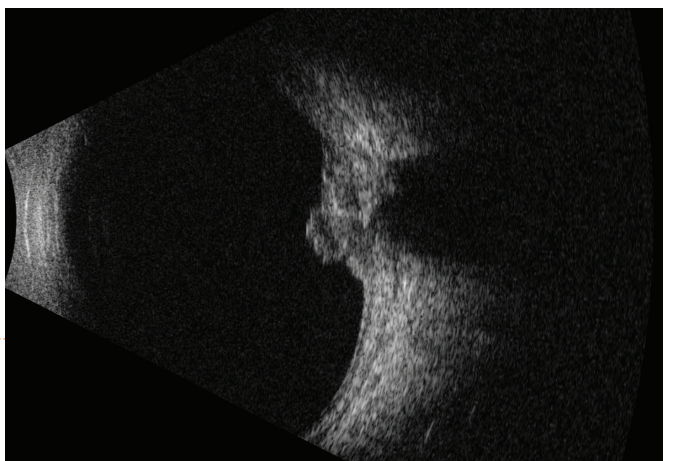
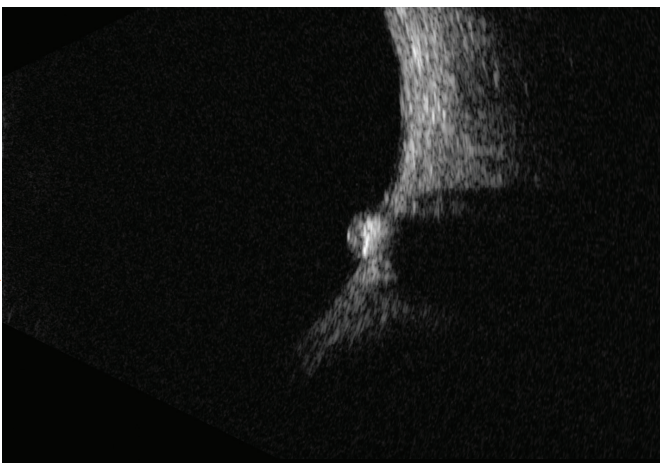
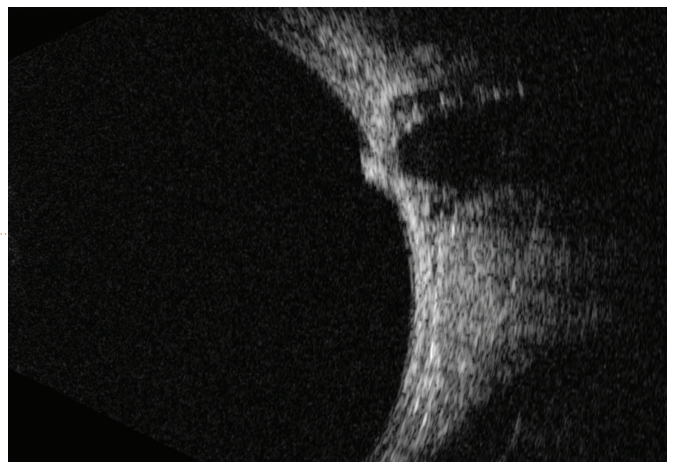
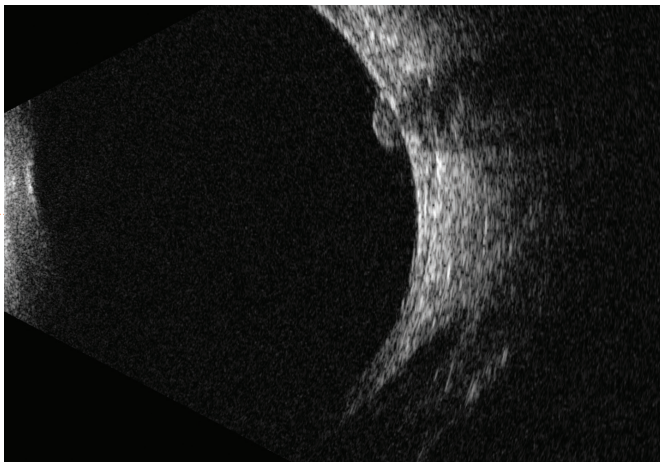


Fig 115: Posterior scleritis showing fluid distension of Tenon's space.

The presence of fluid is the most consistent finding in posterior scleritis. Thickening of the sclera is a less reliable feature. Look for excessive fluid distension of Tenon's space in the peripapillary area.

Fig 116: Posterior scleritis showing thickened sclera and fluid distension of Tenon's space.

Fig 117: Severe posterior scleritis with marked fluid distension of Tenon's space.

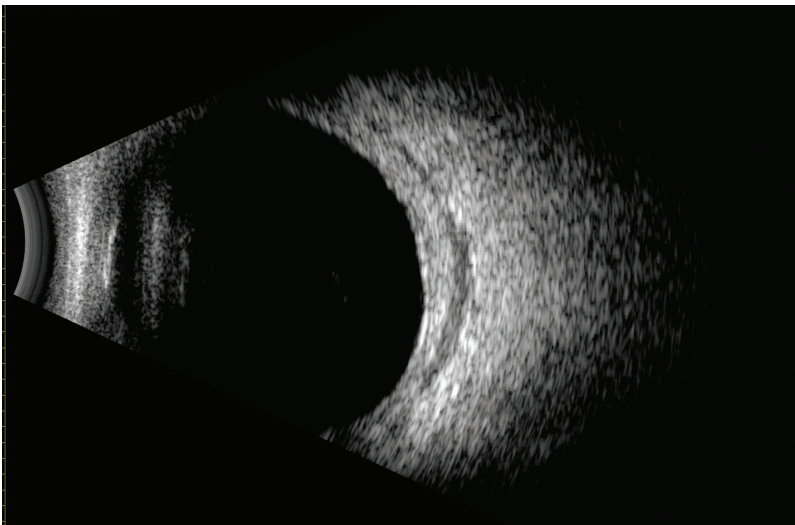
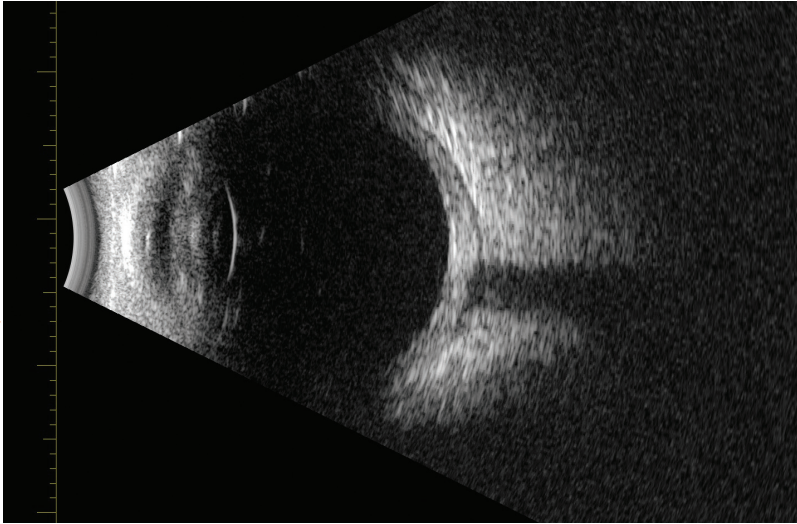
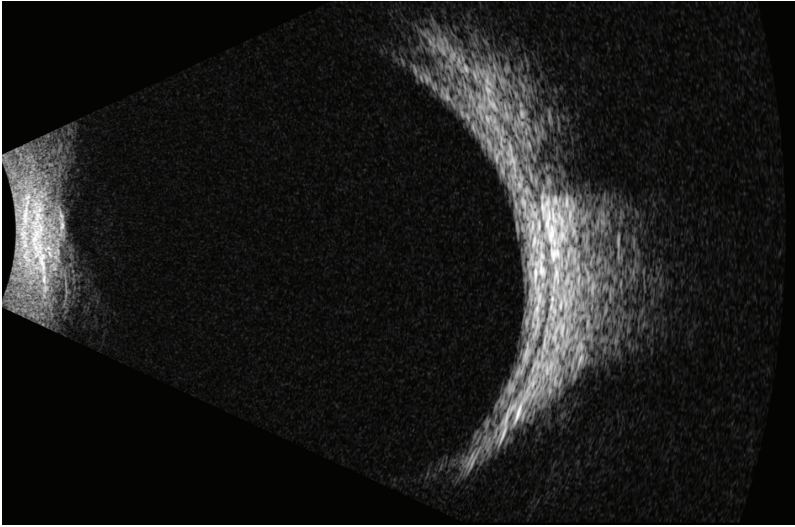


Fig 118: Nodular scleritis after immunosuppression.

Fig 119: Nodular scleritis and myositis.

Fig 120: Nodular scleritis and myositis after steroid treatment.

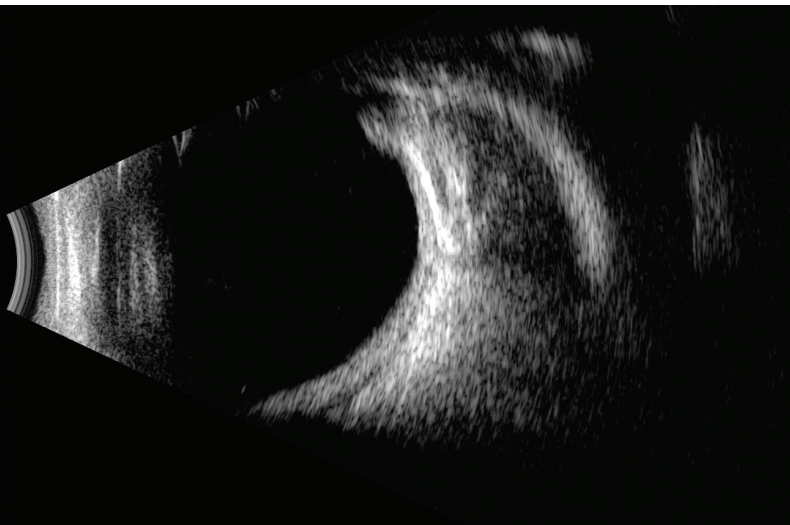
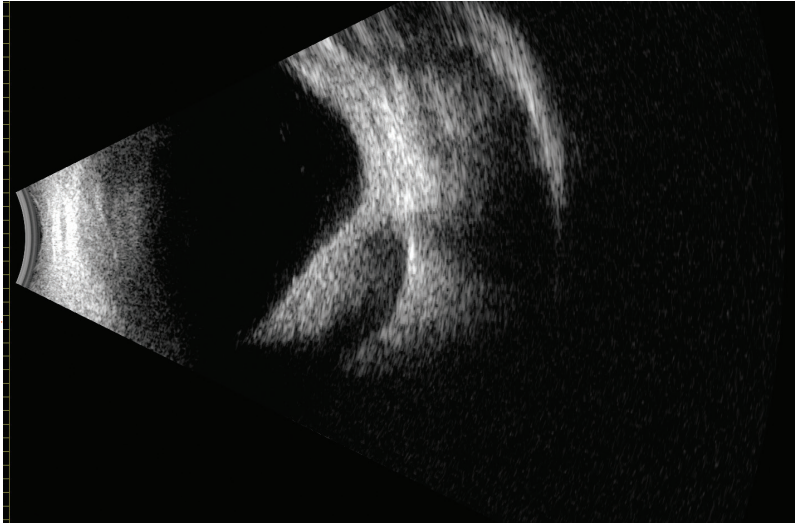
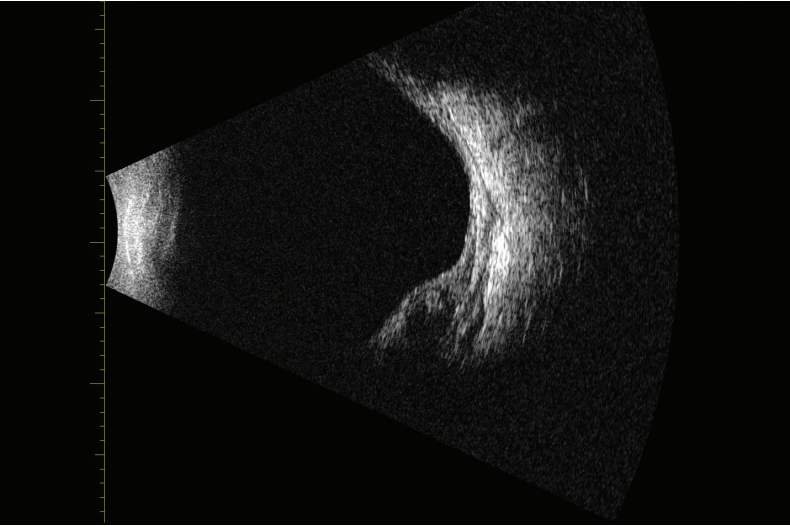


Fig 121: Anterior orbital inflammation, showing hyperdense orbital fat and fluid distension of Tenon's space.

Anterior orbital inflammation is characterised by hyperreflective orbital fat, fluid distension of Tenon's space and hypertrophy of extraocular muscles.

Fig 122: Orbital cellulitis showing hyperdense orbital fat, fluid distension of Tenon's space and thickened sclera.

Fig 123: Inflammatory muscle due to orbital myositis. Note the low reflectivity.

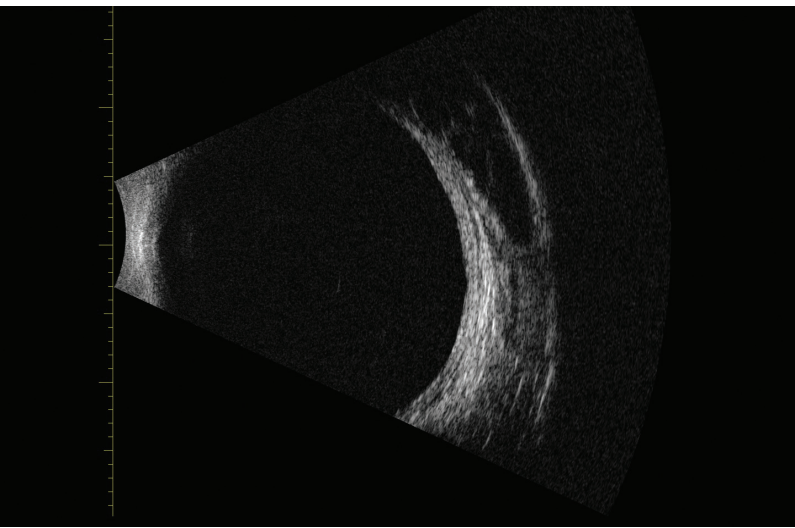
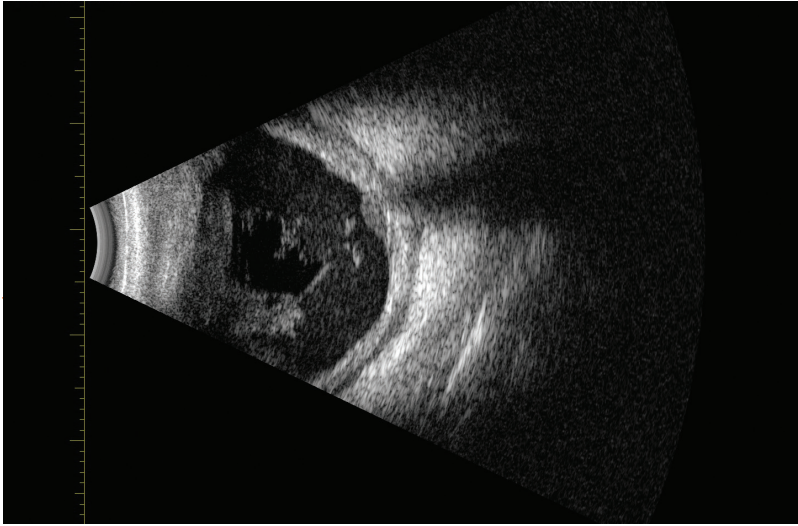
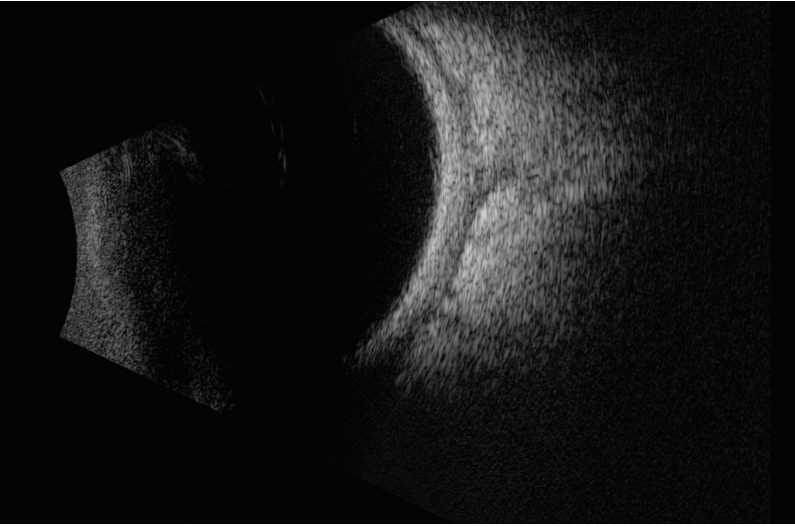


Fig 124: MALT (Mucosal associated lymphoid tissue) showing retinal lymphoid hyperplasia, and retroscleral lymphoma.

Fig 125: Maltoma from lymphoproliferative disease (MALT).

Fig 126: Retinal hamartoma showing calcification.

Hamartoma are often associated with Tuberous Sclerosis. Calcified lesions in the retina and choroid include Retinoblastoma, Retinal Hamartoma, Astrocytic Hamartoma, Osteoma and Hypercalcaemia.

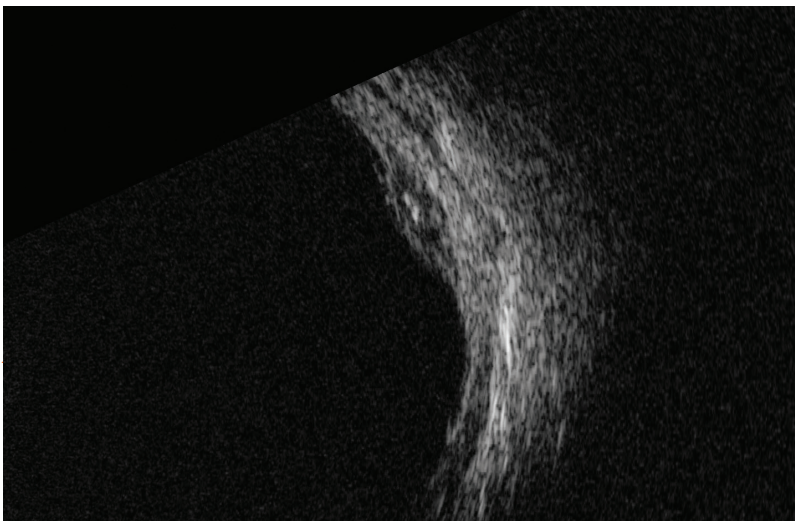
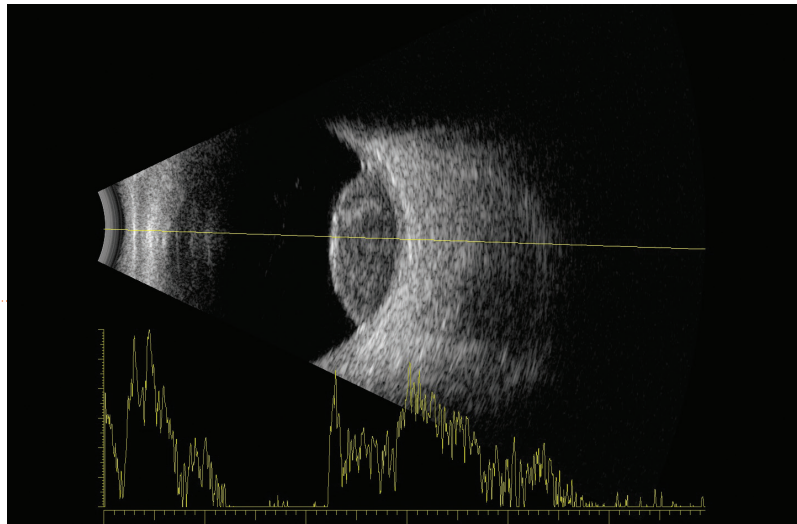
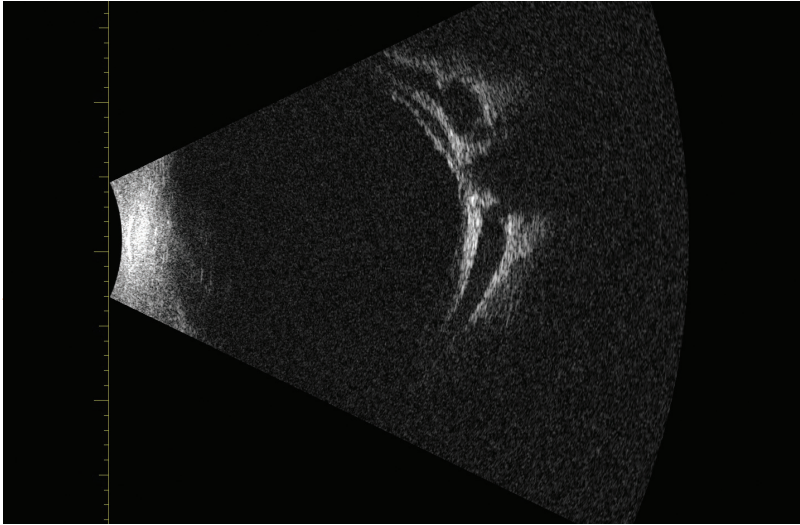


Fig 127.1: OCT of the astrocytic hamartoma.

Fig 127.2: Astrocytic hamartoma showing hyperreflectivity and acoustic shadow.

Fig 128: MM with extrascleral extension.

Choroidal tumours are often associated with extrascleral infiltration usually of low internal reflectivity.

Fig 129: Osophoegeal metastases with extrascleral extension.

IR 30° ART + OCT 30° (8.5 mm) ART (17) Q: 27 EDI [HS]

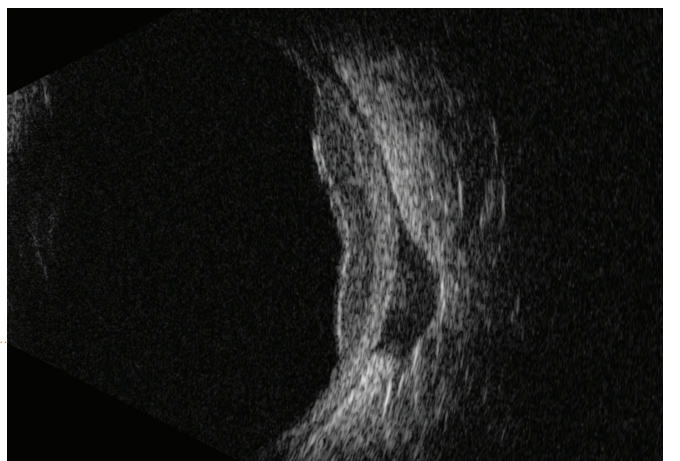
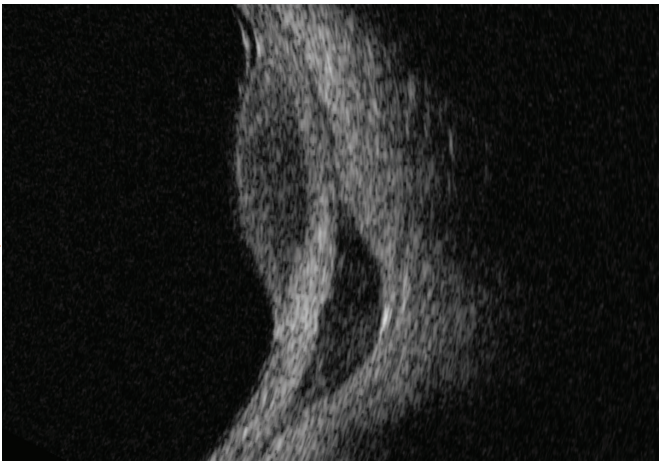
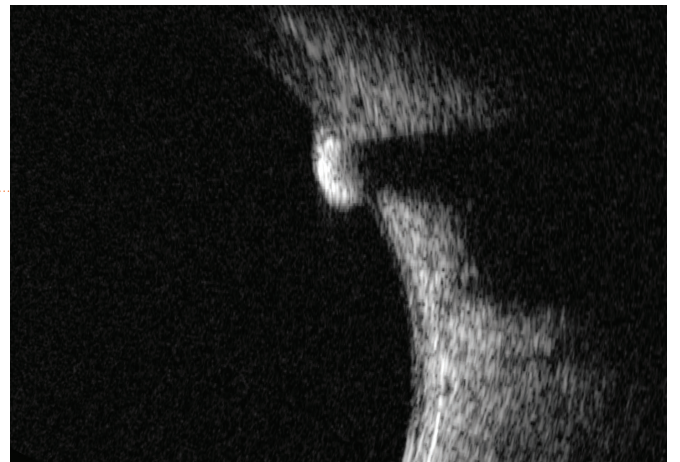
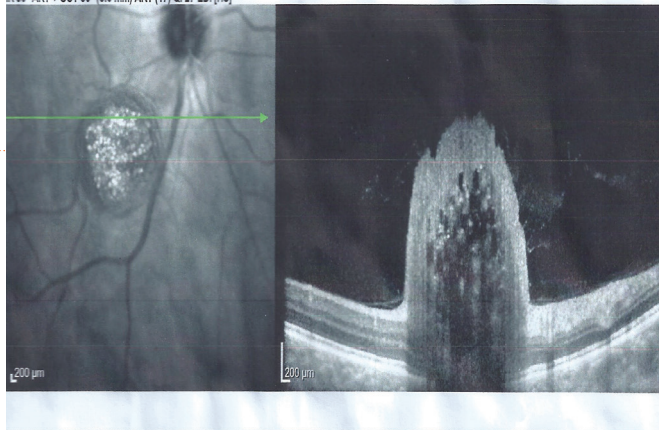


Fig 130: Vortex ampulla often confused with a choroidal lesion.

This can often be confused with mass lesions. The Varix can be identified by asking the patient to look inferiorly when the Varix volume will reduce.

Fig 131: CHRPE showing a hyperreflective choroid but no choroidal excavation.

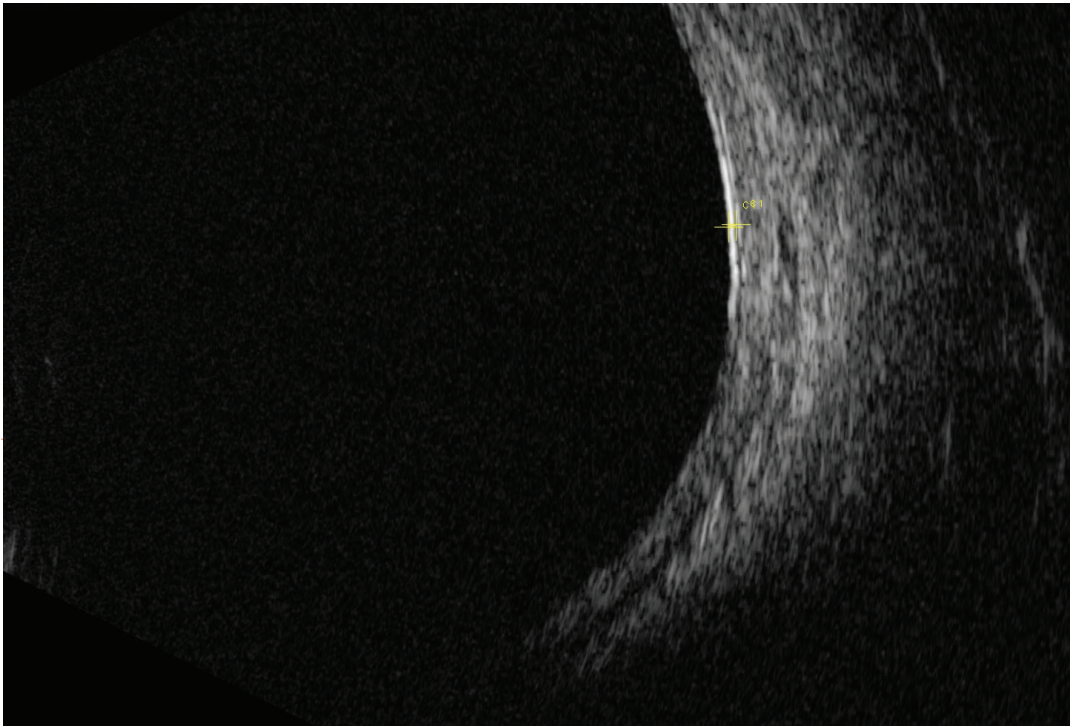
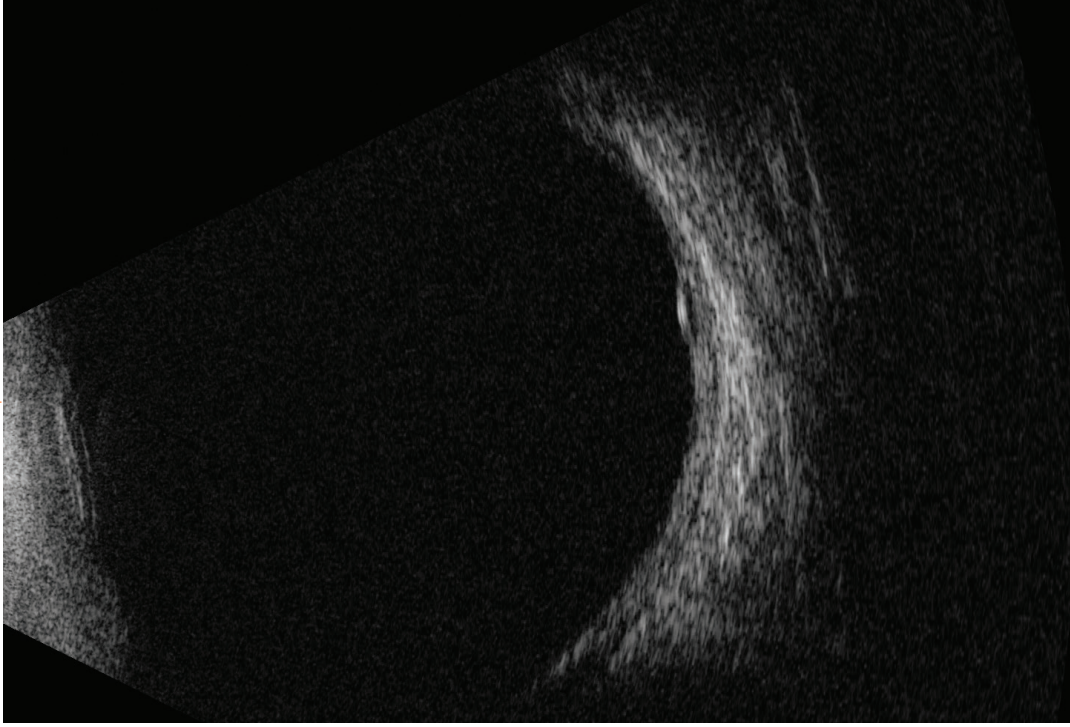


Fig 132: Enlarged muscle in thyroid eye disease.

Fig 133: Extraocular muscle in thyroid eye disease.

Fig 134: Normal extraocular muscle.

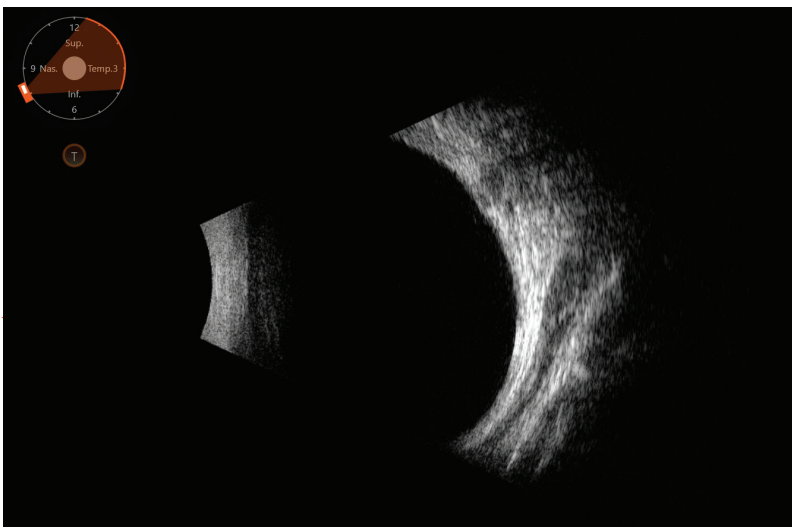
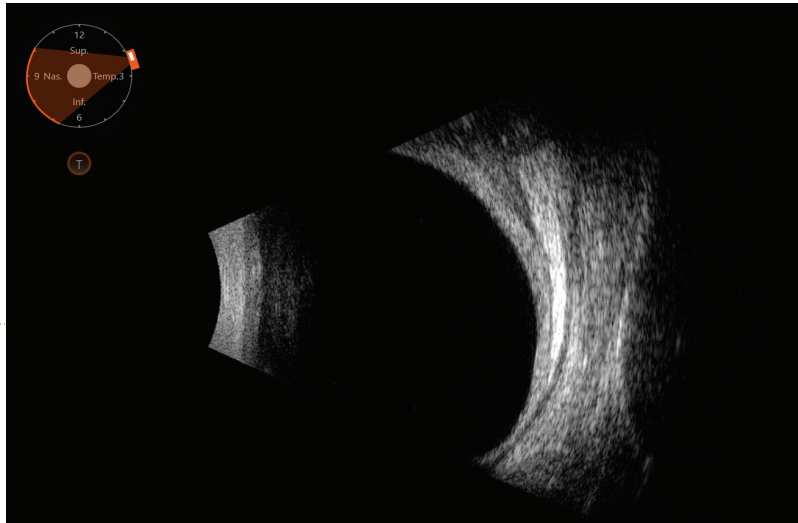
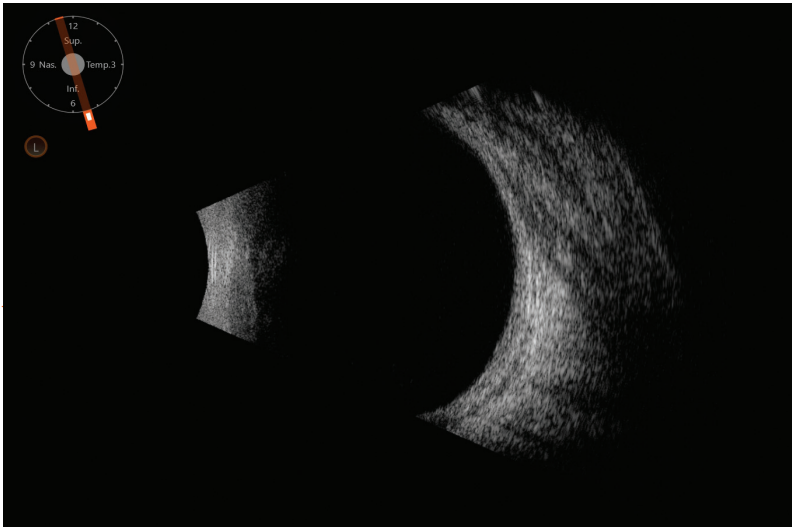


Fig 135: Thin muscle in Brown's syndrome causing ophthalmoplegia.

Fig 136: Myositis. Low reflectivity and hypertrophy of an extraocular muscle.

Fig 137: Anterior orbital inflammation showing markedly distended Tenon's space.

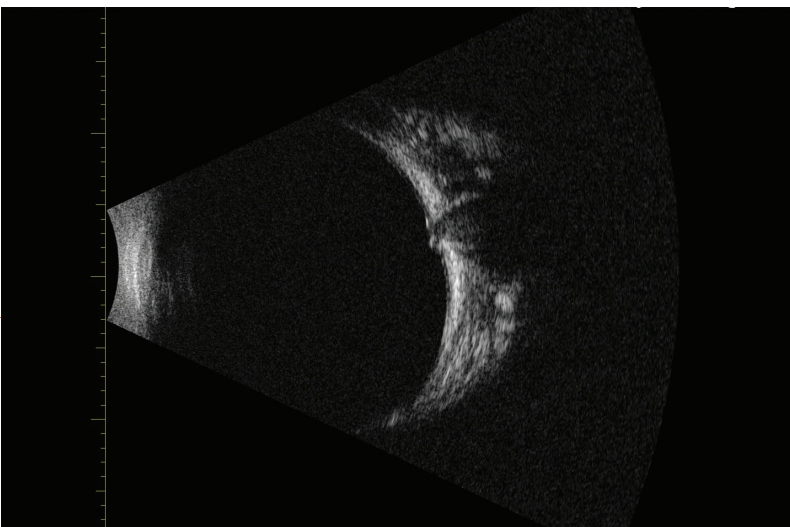
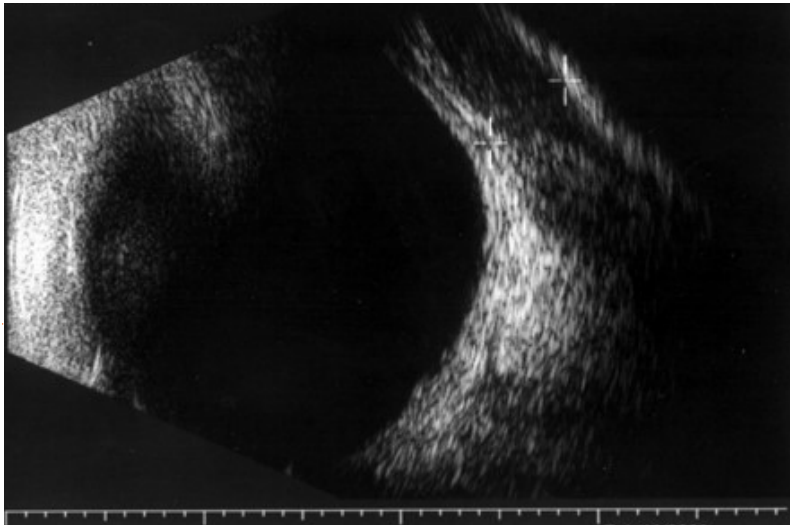
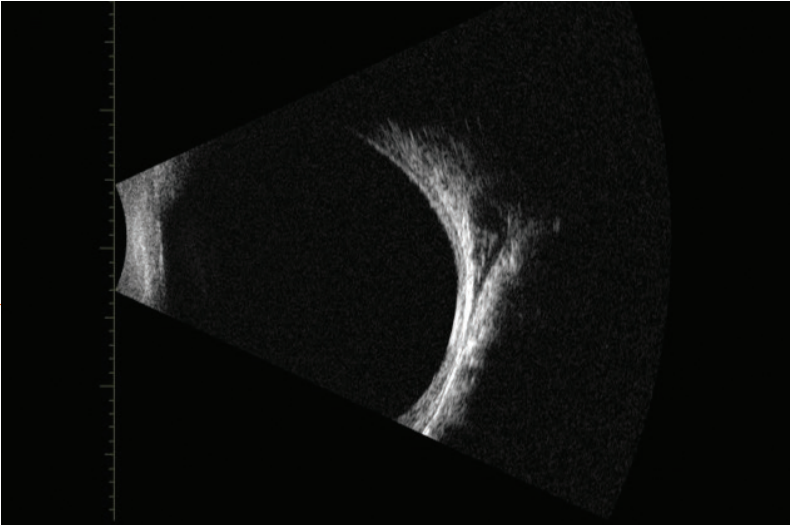
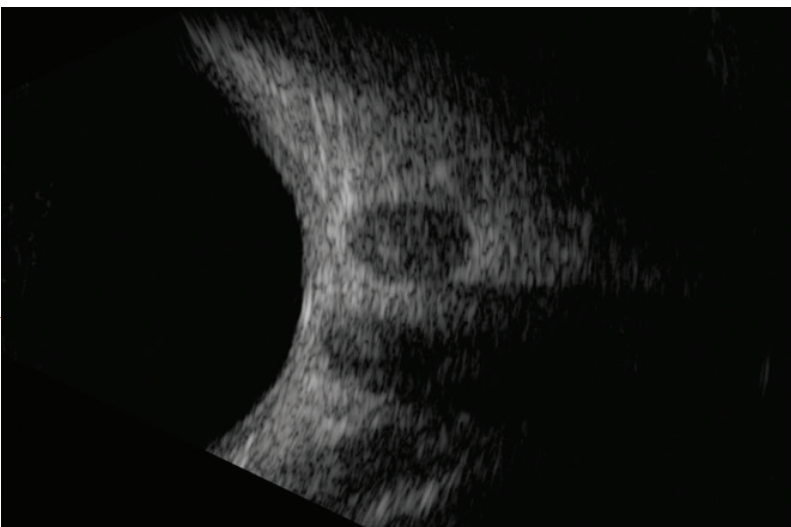
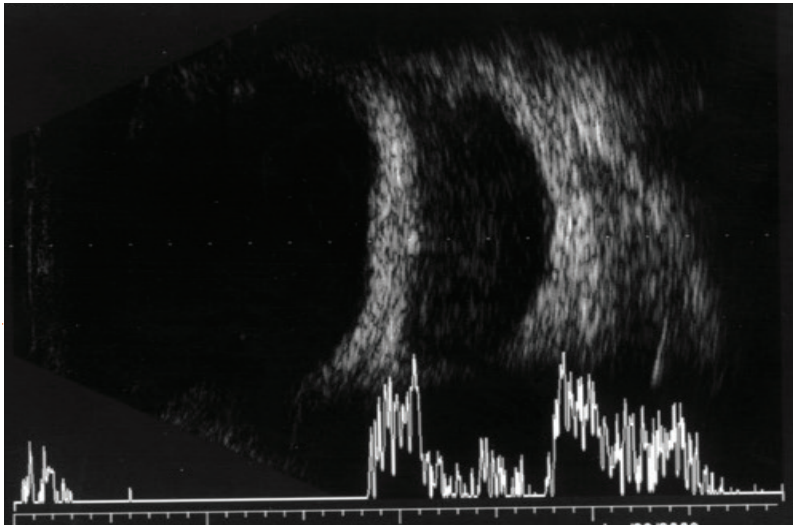
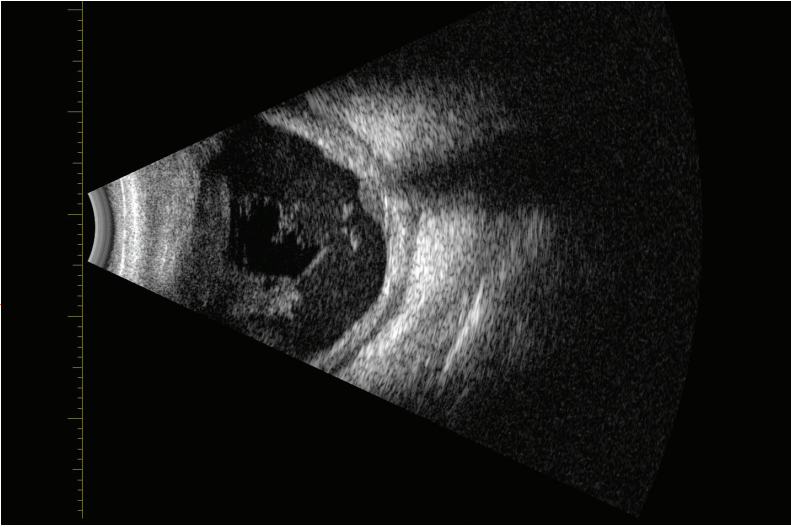
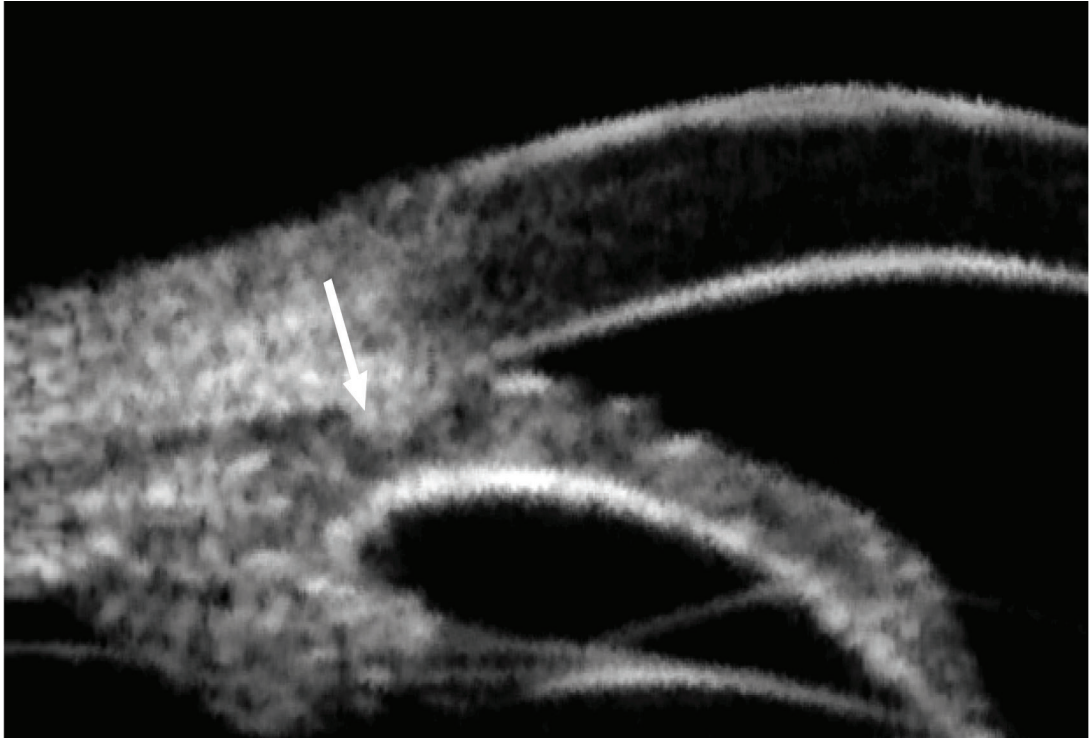


Fig 138: Orbital cellulitis. Hyperdense orbital fat, fluid distension of Tenon's space.

Fig 139: Lymphoma. Low reflectivity with low sound attenuation. Often close to posterior sclera.

Fig 140: Neurofibroma within the muscle sheath.





04

THE BENEFITS OF ULTRASOUND
BIOMICROSCOPY (UBM)

THE BENEFITS OF ULTRASOUND BIOMICROSCOPY (UBM)

Very high frequency ultrasound was introduced in the 1990s by Dr Charles Pavlin, who used a 50 MHz probe to visualise the iridocorneal angle on a longitudinal scan with a resolution of 50 microns. As the technology has developed, this technique has become an often essential tool for analysing the anterior segment. UBM devices have become ever more widely available, thanks to the introduction of multi-functional ocular ultrasound devices that can accommodate posterior segment probes (10 and 20 MHz) and UBM probes (30 to 60 MHz).

OCT devices focused on the anterior segment helped cement anterior segment imaging as an important component of diagnosis and monitoring for various diseases, but the limited penetration offered by OCT behind the iris means a UBM examination is often essential.

The main indications for UBM imaging are iridocorneal angle analysis for glaucoma, particularly narrow-angle glaucoma and tumours of the iris and ciliary body. Scans of the entire anterior segment can also be used to analyse natural lens and lens implants used in cataract or refractive surgery. The positioning of UBM probe with regard to the corneal margin and the sclera also enables very effective imaging of the retinal periphery.

UBM TECHNIQUE AND EXAMINATION

UBM probes use frequencies of between 30 and 60 MHz. Quantel Medical's 50-MHz linear probe makes it easier to analyse the corneal signal on scans of the entire anterior segment.

Examinations can be performed with either a Clear Scan probe cover, which allows the scan to be performed with the patient sitting up, or with a flat probe cover, with the patient laying down.

Depending on the selected zoom, the images can be limited to a longitudinal scan of an angle, or a full scan of the entire anterior segment.

Longitudinal scans provide very good visualisation of the iridocorneal angle and also show the scleral spur (Fig 141). Scans of the entire anterior segment pass through the corneal apex, the pupillary area of the anterior lens capsule, and the central area of the posterior lens capsule.

Longitudinal scans can be used to measure angle opening distance, while scans of the entire anterior section can be used to measure the distance from angle to angle and sulcus to sulcus, lens vault, and anterior chamber depth. (Fig 142)

ANGLE OPENING DISTANCE (AOD) ANALYSIS

The advantage of UBM is that it can analyse AOD and changes in AOD based on pupil dilation or accommodation.

OCT and UBM devices offer different digital approaches, including AOD measurement at 500 or 750 microns (Fig 143) and Angle Recess Area (ARA) or Trabecular-Iris Space Area (TISA) measurement.

In current practice, angle opening distance can be assessed in the four main meridians in scotopic conditions, in order to detect the risk of angle closure.

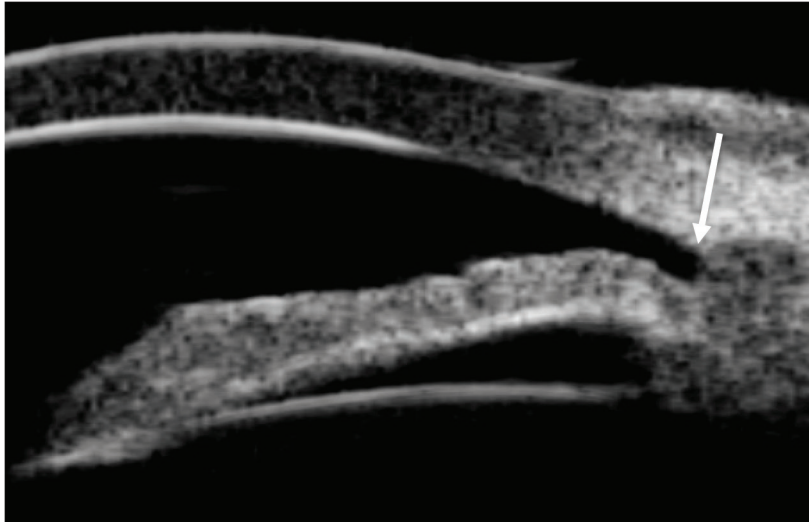


Fig 141: Meridian scan of the angle with visualization of scleral spur.

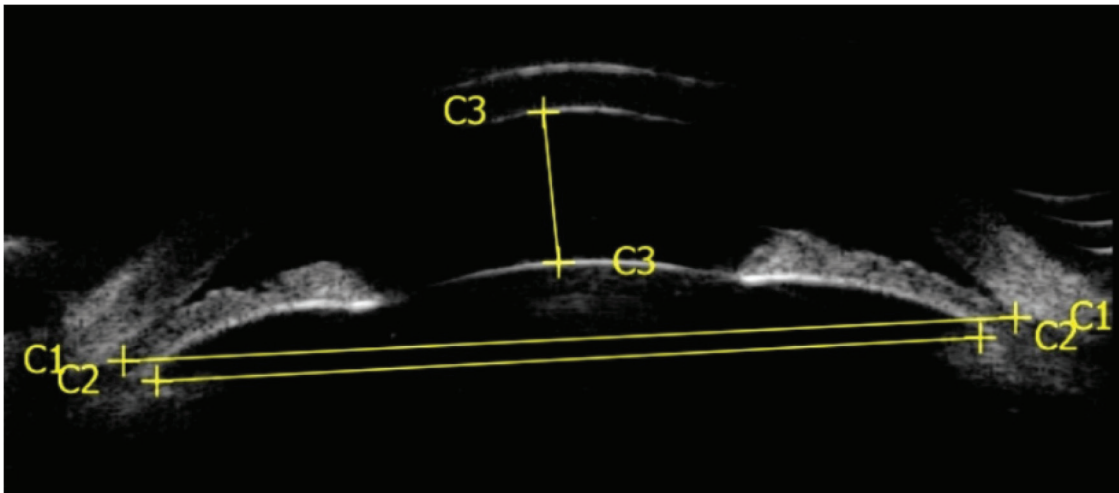


Fig 142: Anterior segment UBM scan with measurement of angle to angle (C1), sulcus to sulcus (C2) and anterior chamber depth (C3).

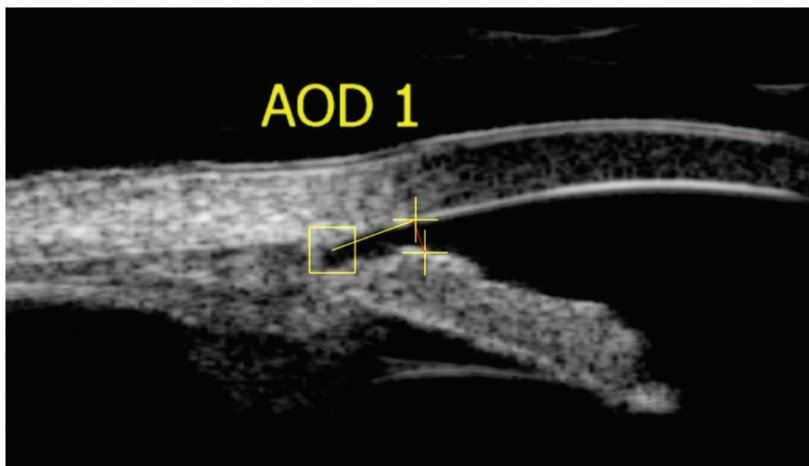


Fig 143: Angle opening distance at 500 micron from scleral spur : AOD 500.

UBM ANALYSIS OF ANGLE CLOSURE MECHANISMS

- Pupillary block: this is indicated by the presence of angle closure with the iris bowing forward outwards. (Fig 144)
- Plateau iris appears in UBM images as angle closure with anterior ciliary processes and an absence of the ciliary sulcus, caused by indentation of the iris root by the ciliary processes. (Fig 145)
- Anterior insertion of the iris root: this anatomical variation is linked to the anatomy of the angle, with the iris root inserted very close to, or occasionally on, the scleral spur. (Fig 146)
These three mechanisms are often present together in variable proportions, making UBM analysis very useful in gaining a better understanding of the angle closure mechanism. UBM is indispensable after peripheral iridotomy when the angle has not reopened effectively.
- UBM can also identify areas of peripheral anterior synechiae. (Fig 147)

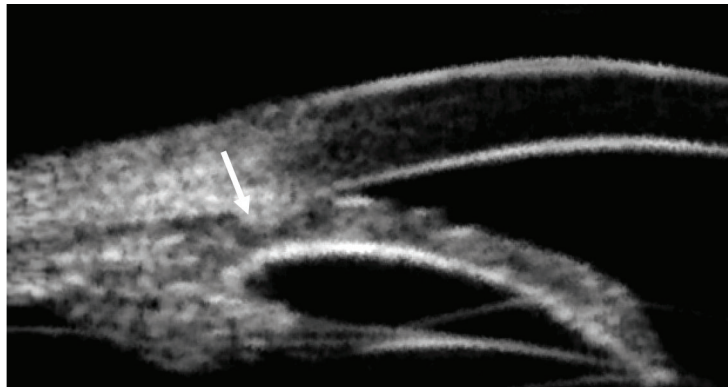


Fig 144: Angle closure with pupillary block characterized by anterior iris bowing and no pathway for aqueous humor to trabeculum. Posterior positioning of ciliary processes shows no plateau iris mechanism.

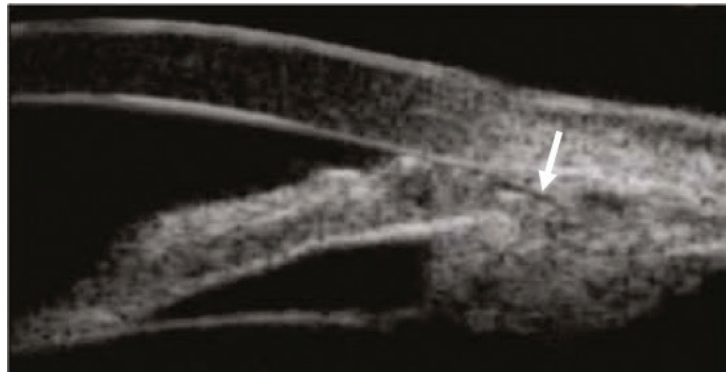


Fig 145: Plateau iris mechanism with anterior positioning of ciliary processes, closed angle and no sulcus visible.

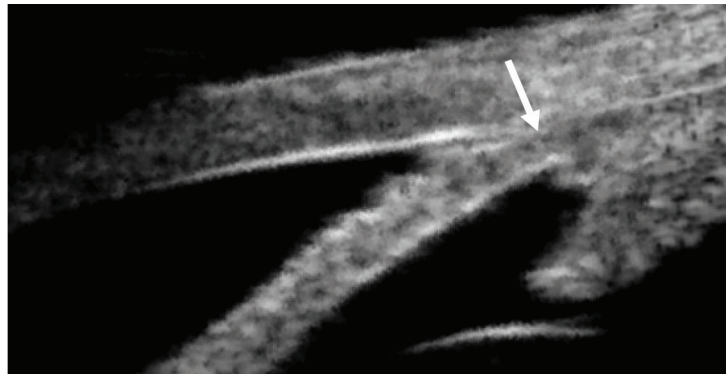


Fig 146: Anterior insertion of iris root very close to scleral spur.

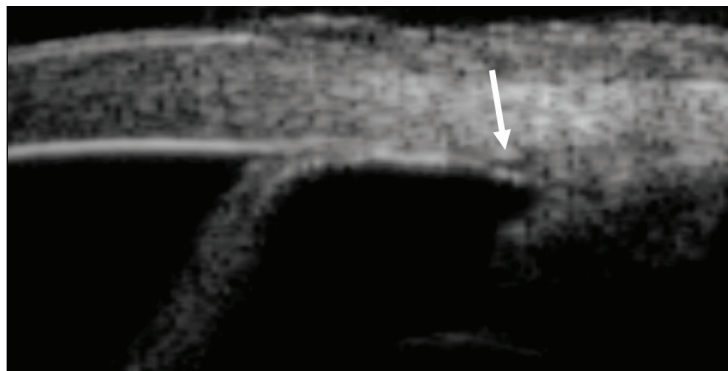


Fig 147: Large anterior irido-corneal synechiae.

- Iridociliary cysts: varying hugely in volume, these cysts can, when isolated, cause localised angle closure. UBM is essential when removing solid iridociliary lesions. (Fig 148)
In cases of extensive polycystic disease, the appearance of the angle may be clinically suggestive of plateau iris, but only a UBM exam can provide the precise visualisation required to detect the meridians not affected by cysts so that the iridotomy treatment can be targeted correctly. (Fig 149)
- Malignant glaucoma: when the iris and ciliary body tip forward this can cause malignant glaucoma with almost total loss of the anterior chamber. (Fig 150)

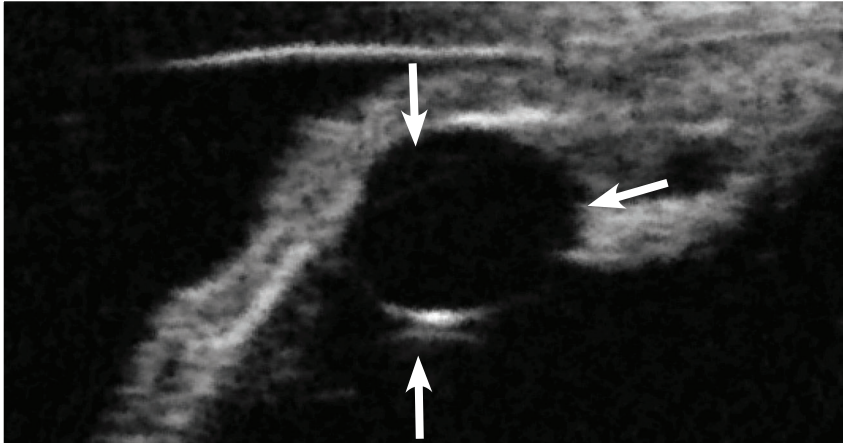


Fig 148: Closed angle with iris cyst pushing the iris root forward.

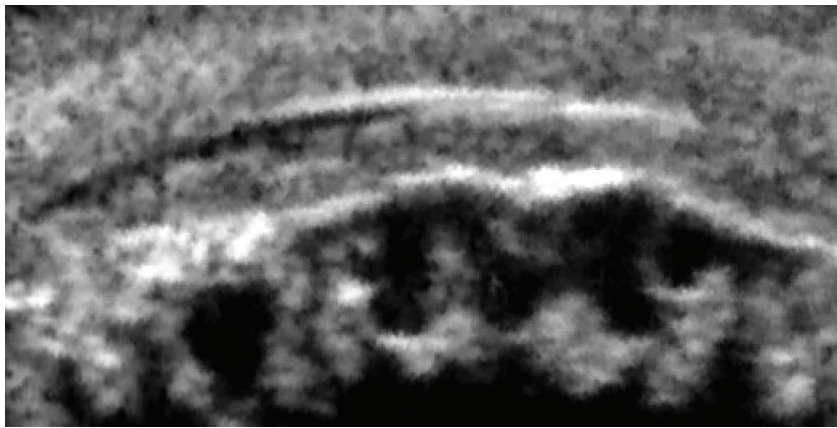


Fig 149: Multiple cysts of the iris and ciliary processes.

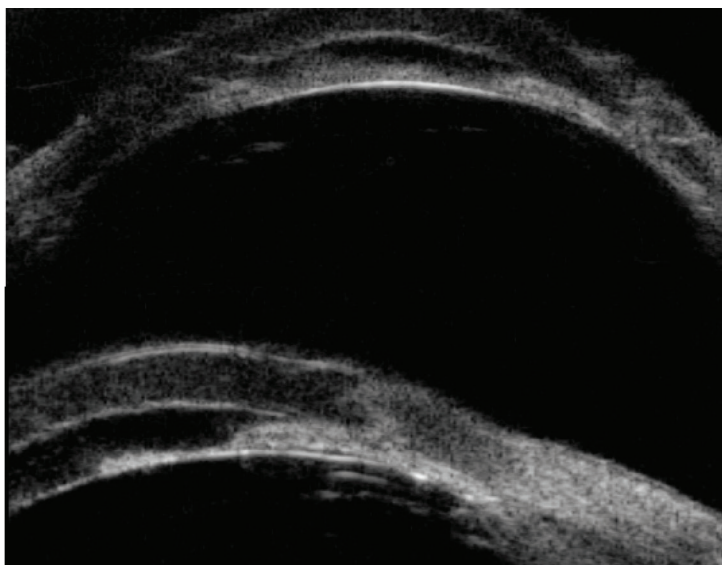


Fig 150: Malignant glaucoma with reduction of anterior chamber depth and anterior positioning of lens and iris.

OPEN ANGLE ANALYSIS

For patients being monitored for open-angle glaucoma with a narrow angle, UBM can be used to rule out or confirm the presence of mixed glaucoma that gradually led to a risk of temporary bouts of angle closure. UBM can also identify inversion of the iris curvature for patients with a predisposition to pigmentary glaucoma. (Fig 151)

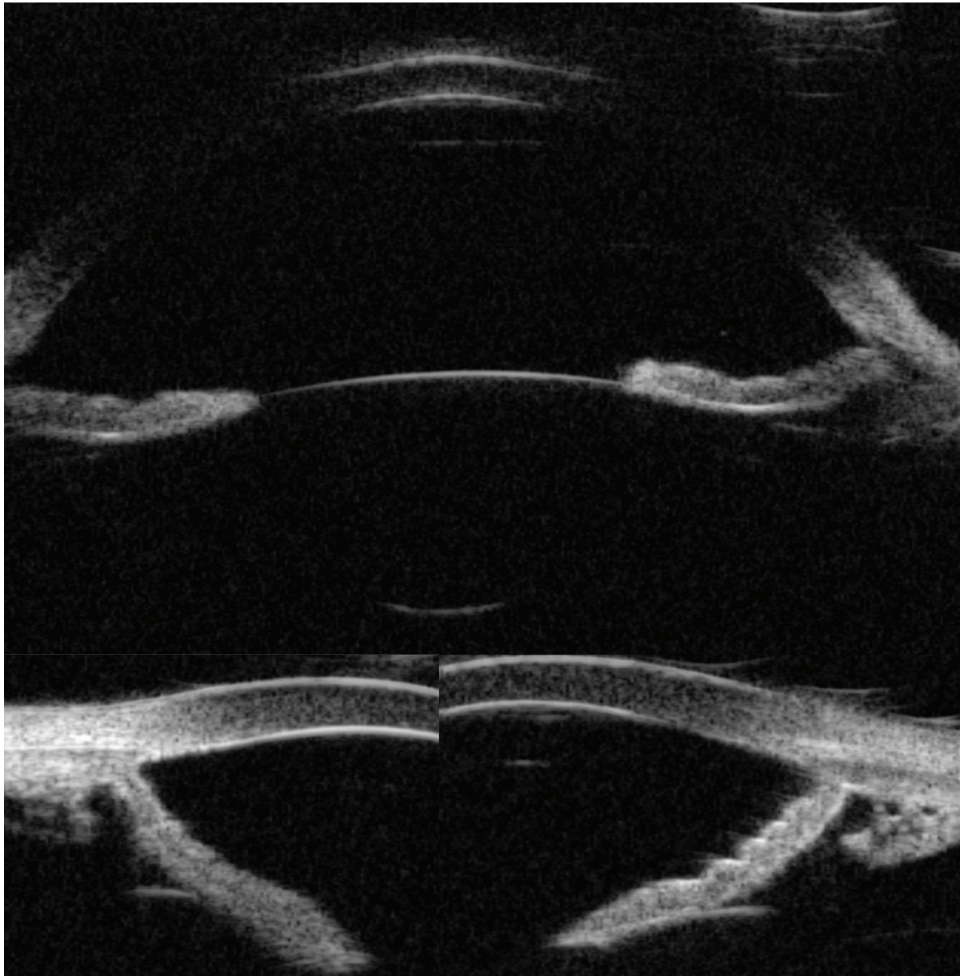


Fig 151: Pigmented glaucoma with posterior iris bowing.

POST-TREATMENT ANALYSIS

- **After peripheral iridotomy:**

UBM can be used to identify whether or not the peripheral iridotomy achieved full penetration and to assess the impact on the risk of angle closure. After a successful iridotomy, the iris will appear straight and will no longer bulge forwards. (Fig 152)

A penetrating iridotomy may nevertheless be associated with the continued presence of a narrow or closed angle, due to insertion of the iris root, plateau iris (Fig 153) or polycystic disease.

Inversion of the iris curvature, found with pigmentary glaucoma, can generally be fully reversed by iridotomy.

- **After filtration surgery:**

UBM provides a clear image of the filtration surgery site, with very good visualisation of the trabecular meshwork for deep sclerectomy (Fig 154). It can also be used to assess the filtering bleb or the obstacle reducing drainage, in the case of trabeculotomy. (Fig 155)

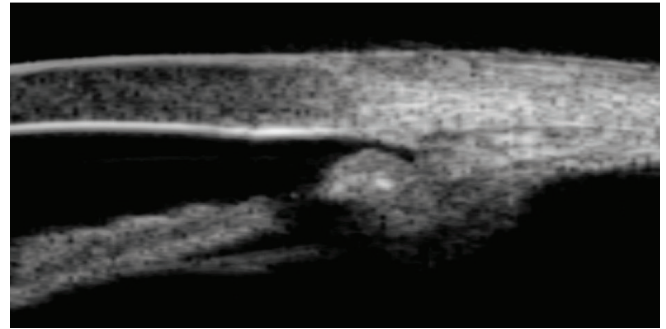
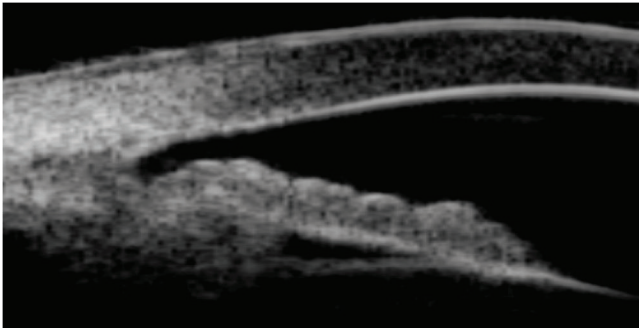


Fig 152: Perforating iridotomy with no bowing of the iris showing no pupillary block. Anterior positioning of ciliary processes without plateau iris mechanism.

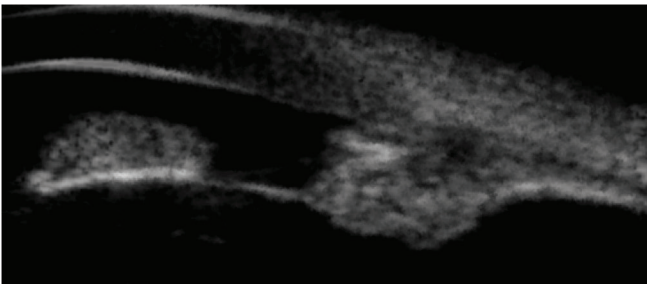


Fig 153: Iridotomy with plateau iris mechanism remaining due to ciliary processes anterior rotation.

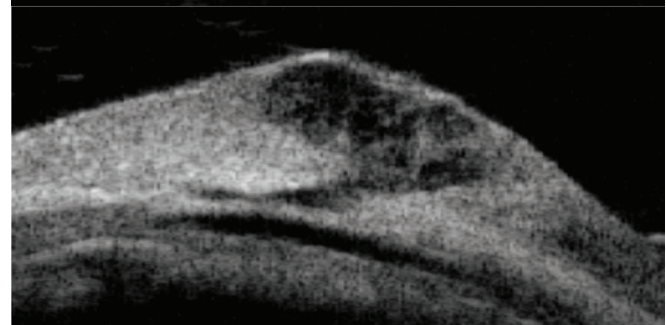
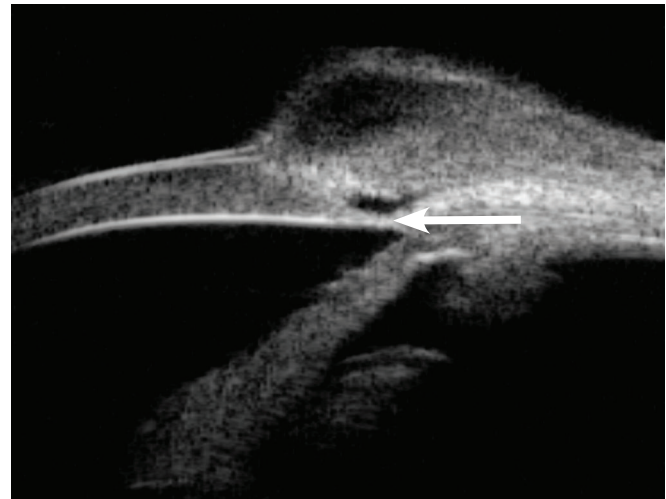


Fig 154: Deep sclerectomy with visualisation of trabeculum in the angle.

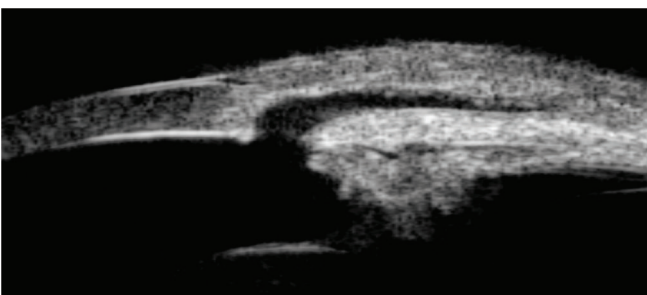


Fig 155: Trabeculectomy with moderate filtering bleb.

UBM AND TUMOURS

UBM plays a key role in tumours of the iris and ciliary body, facilitating diagnosis and pre-treatment measures as well as progression monitoring after conservative treatment.

It can be difficult to access lesions of the retinal periphery with optical devices. UBM is the only imaging tool that can precisely visualise these lesions, whether naevi or melanomas.

UBM can also image the anterior border of lesions in the ora serrata and check whether there is ciliary involvement. (Fig 156)

In the case of ciliary lesions, longitudinal and transverse scans can measure the length and thickness of the lesions, to serve as the basis for progression monitoring.

Differential diagnosis between iridociliary cysts and solid lesions is relatively straightforward with UBM: cysts appear liquid and suspected lesions appear solid.

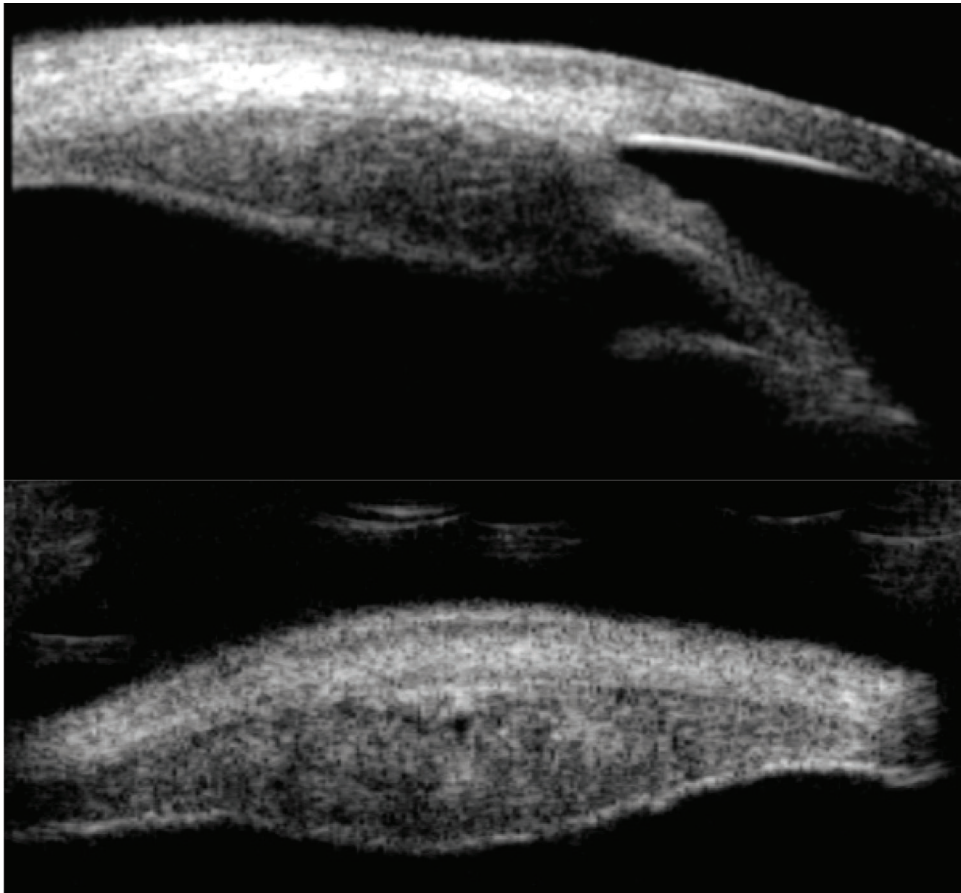


Fig 156: Choroidal and ciliary melanoma.

UBM AND IMPLANTS

Transverse images of the entire anterior segment can be used to identify the position of a posterior chamber intra ocular lens (IOL), by assessing the position of the implant surface relative to the pupil and the position of its footplates. If a footplate is positioned in the ciliary sulcus, this can sometimes cause indentation of the iris root. (Fig 157)

For anterior chamber phakic IOLs, UBM imaging can be used to check the safety distances between the implant and the cornea (Fig 158), and can also assess the position of the implant feet in the iridocorneal angle, as well as the iris attachment.

The current trend towards using phakic IOLs in the posterior chamber makes UBM the number one option for pre-surgical analysis, since it offers sulcus-to-sulcus measurement, which enables better sizing of the implant than white-to-white measurement. UBM can also be used to detect anterior positioning of the ciliary processes, which can decentre the implant.

After surgery, UBM can sometimes detect excessive pressure between the implant legs and the ciliary body, which can cause either subluxation of the implant or, occasionally, pain, in the worst cases of oversized implants. (Fig 159)

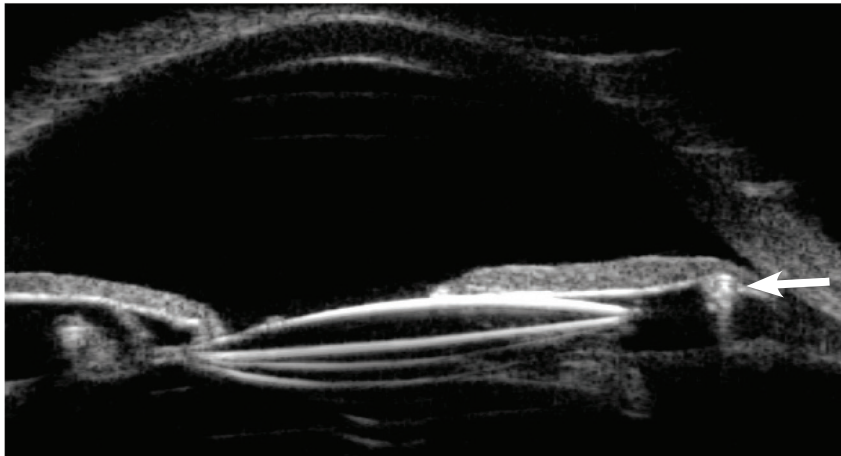


Fig 157: Posterior IOL luxation with iris root indentation by footplate of the implant.

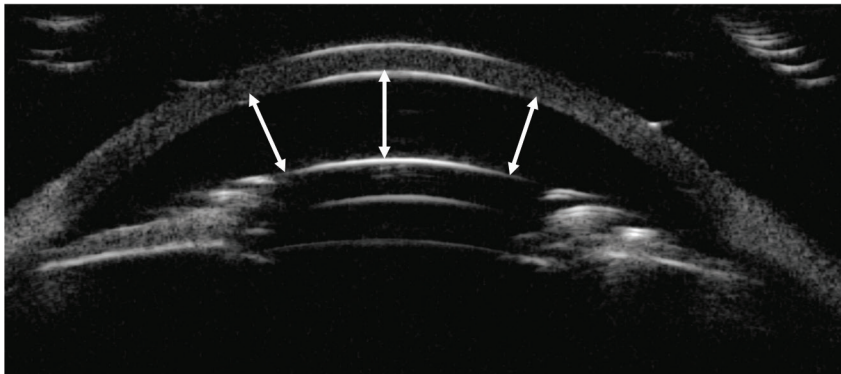


Fig 158: Anterior chamber phakic IOL with security distance measurement between corneal endothelium and IOL.

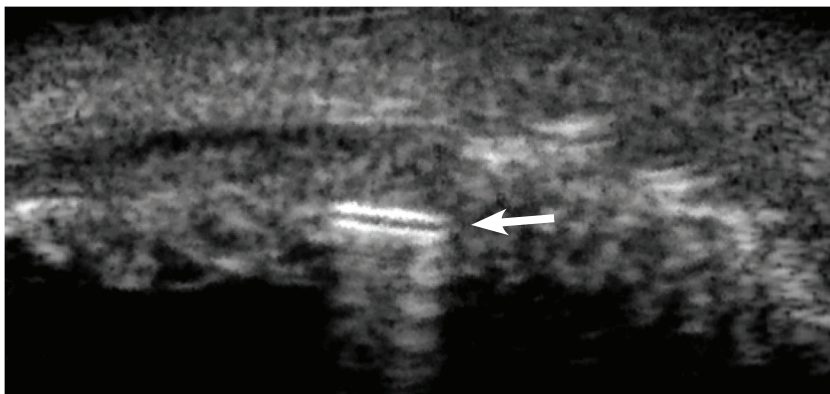


Fig 159: Transverse scan with visualization of ciliary processes and IOL footplate indentation in case of over estimated implant sizing.

UBM AND TRAUMA

UBM can play a useful role in the assessment of eye trauma by identifying any reduction in the iridocorneal angle obscured by hyphema, or subluxation of the lens or lens implant. (Fig 160)

UBM AND THE RETINAL PERIPHERY

UBM analysis of the retinal periphery offers better visualisation of both peripheral solid lesions and peripheral wall thickness. For example, choroidal detachment extending to the ciliary body can be identified based on the appearance of numerous internal trabeculae. (Fig 161)

In case of hyaloiditis, the inflammatory vitreal defects can be identified, as well as the extent of peripheral vitreous involvement.

CONCLUSION

UBM examination of the anterior segment is becoming increasingly accessible thanks to modern ultrasound devices. UBM's resolution and penetration mean it can offer very good diagnosis and monitoring of angle defects, as well as thickenings of the iris and ciliary body and, in some cases, the retinal periphery.

This very specific benefit of UBM makes it the perfect partner for OCT examinations, which are more limited in terms of penetration.

The UBM imaging technique can sometimes appear difficult to learn, but can be taught fairly easily using today's devices, which work with covered probes and offer variable zoom.

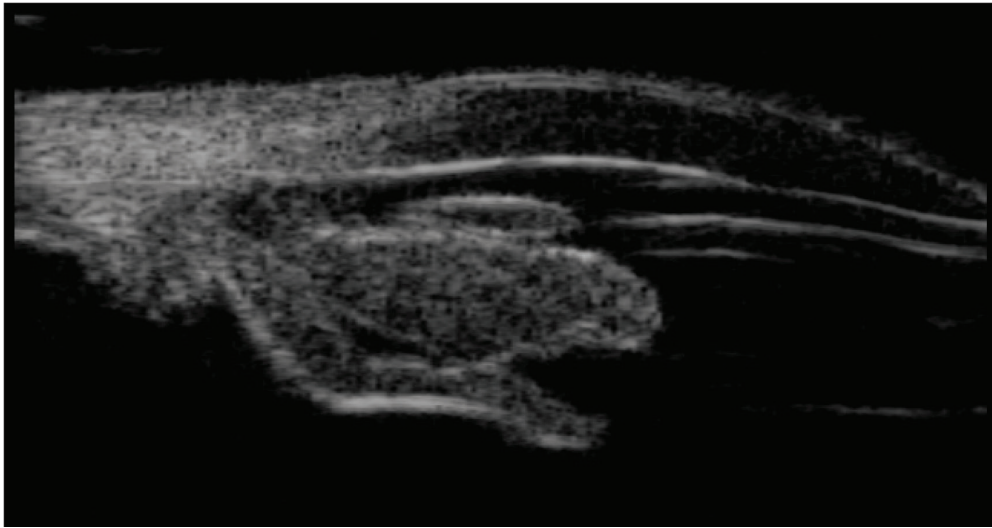


Fig 160: Post trauma angle recess with hyphema.

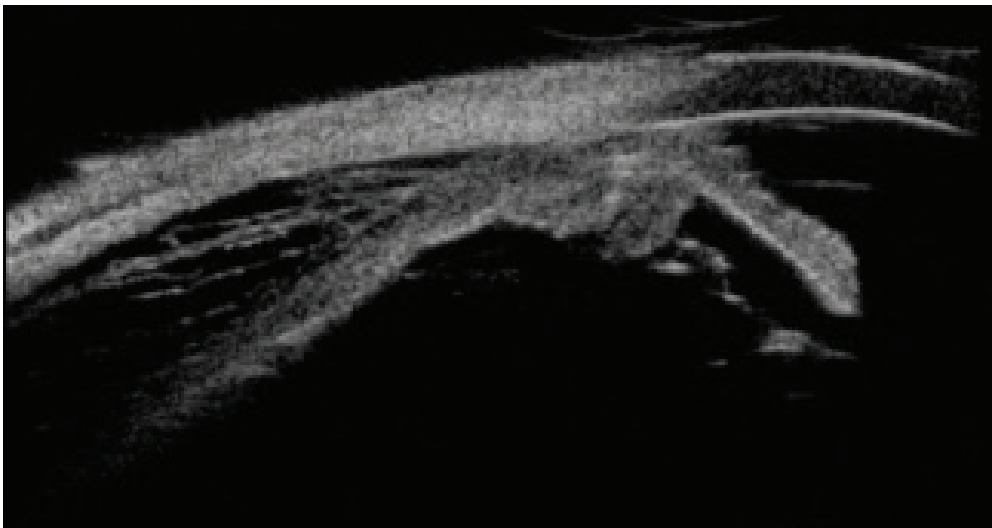


Fig 161: UBM meridian scan focused on periphery with choroidal detachment: the angle is closed with plateau iris mechanism.

Collection Librairie Médicale Théa



Laboratoires Théa
12 Rue Louis Blériot - ZI du Brézet
63017 Clermont-Ferrand cedex 2 - France
Tel. +33 (0)4 73 98 14 36 - Fax +33 (0)4 73 98 14 38
www.laboratoires-thea.com



11, rue du Bois Joli
CS 40015
63800 Cournon d'Auvergne Cedex
www.quantel-medical.com