

OCT & RETINA

Marie-Bénédicte Rougier, MD, PhD, FEBO
Prof. Marie-Noëlle Delyfer, MD, PhD, FEBO
Prof. Jean-François Korobelnik, MD, FEBO
Bordeaux University Hospital, France



Table of Contents

1. Optical coherence tomography in healthy subjects	p. 13
2. Diseases of the vitreoretinal interface	p. 17
2.1. Vitreomacular traction	p. 18
2.2. Macular hole.....	p. 20
2.3. Lamellar hole.....	p. 26
2.4. Epimacular membrane.....	p. 28
3. Macular oedemas	p. 33
3.1. Diabetes	
3.1.1. Focal macular oedema	p. 34
3.1.2. Mixed macular oedema	p. 40
3.1.3. Diffuse macular oedema.....	p. 42
3.1.4. Tractional macular oedema.....	p. 44
3.1.5. Mixed maculopathy (oedematous and ischaemic)	p. 46
3.2. Retinal vein occlusion	
3.2.1. Central vein occlusion.....	p. 48
3.2.2. Branch vein occlusion.....	p. 50
3.3. Retinal artery occlusion	
3.3.1. Central artery occlusion	p. 52
3.3.2. Branch artery occlusion	p. 54
3.4. Inflammation	
3.4.1. Uveitis	p. 56
3.4.2. Irvine-Gass syndrome.....	p. 60
4. Macular telangiectasia	p. 63
5. AMD	p. 69
5.1. Early onset AMD or ARM	
5.1.1. Serous drusen.....	p. 70
5.1.2. Reticular drusen.....	p. 76
5.1.3. Cuticular drusen.....	p. 80
5.2. Atrophic AMD	p. 82
5.3. Exudative or neovascular AMD	
5.3.1. Typical forms	
5.3.1.1. Active forms.....	p. 90
5.3.1.2. Cicatricial forms	p. 96
5.3.1.3. Retinal pigment epithelial tear	p. 102
5.3.2. Polypoidal vasculopathy.....	p. 104
5.3.3. Chorioretinal anastomoses.....	p. 106
6. Other degenerative macular disorders	p. 109
6.1. Pseudovitelliform dystrophy.....	p. 110
6.2. Angioid streaks	p. 112

7. Hereditary retinal dystrophies	p. 115
7.1. Stargardt's maculopathy	p. 116
7.2. Retinitis pigmentosa	p. 118
7.3. Cone dystrophy	p. 122
7.4. Best's disease	p. 124
7.5. Central areolar choroidal sclerosis	p. 130
7.6. X-linked retinoschisis	p. 132
8. Myopia	p. 137
8.1. Choroidal thinning	p. 138
8.2. Dome-shaped macula	p. 140
8.3. Bruch's membrane rupture	p. 142
8.4. High myopia neovascularisation	p. 144
8.5. High myopia foveoschisis	p. 146
9. Central serous chorioretinopathy (CSCR) and other serous retinal detachments	p. 149
9.1. Typical CSCR	p. 150
9.2. Chronic CSCR and diffuse retinal pigment epitheliopathy	p. 156
9.3. Other causes of serous retinal detachment	
9.3.1. Hypertension	p. 160
9.3.2. Purtscher's retinopathy	p. 162
9.3.3. Colobomatous pit	p. 164
9.3.4. Iatrogenic causes	p. 166
9.3.5. Rhegmatogenous retinal detachment	p. 168
9.3.6. Postoperative causes	
9.3.6.1. Episcleral surgery outcomes	p. 170
9.3.6.2. Subretinal perfluorocarbon liquids	p. 172
10. Inflammatory diseases	p. 175
10.1. Multiple evanescent white dot syndrome (MEWDS)	p. 176
10.2. Acute multifocal placoid pigment epitheliopathy (AMPPE)	p. 178
10.3. Serpiginous choroiditis	p. 180
10.4. Harada's disease	p. 182
11. Chloroquine-induced maculopathy	p. 185
12. Tumours	p. 189
12.1. Choroidal naevus	p. 190
12.2. Choroidal melanoma	p. 192
12.3. Choroidal metastasis	p. 194
12.4. Choroidal osteoma	p. 196

1. Optical coherence tomography in healthy subjects

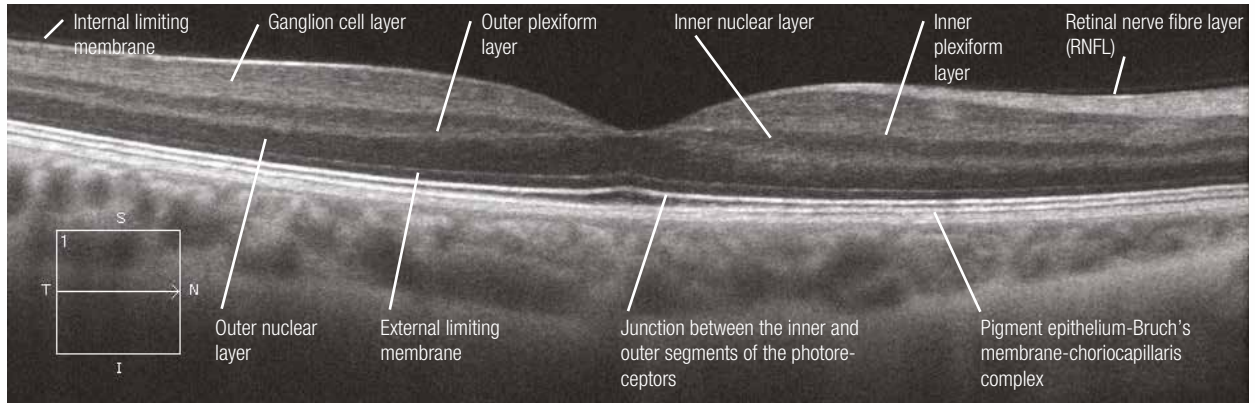
The OCT examination is based on the light-reflecting properties of the retinal tissue. The transverse sections obtained using the latest generation machines have an axial resolution of around 3 to 8 microns and a transverse resolution of 15 to 20 microns. The different retinal layers appear as a grey (or colour) scale that ranges from white to black (or red to blue). The more reflective the tissue is, the whiter the image will be (or redder if a colour scale is used). The less reflective the tissue is, the blacker (or bluer) the image will appear.

The first hyperreflective layer visible in the majority of cases (but not systematically) is the internal limiting membrane. The nerve fibre, inner and outer plexiform layers are also hyperreflective, while the inner nuclear and outer nuclear layers are hyporefective. The ganglion cell layer is moderately reflective. It should be noted that, under normal conditions, the Henle's fibre layer (part of the outer plexiform layer) is not visible.

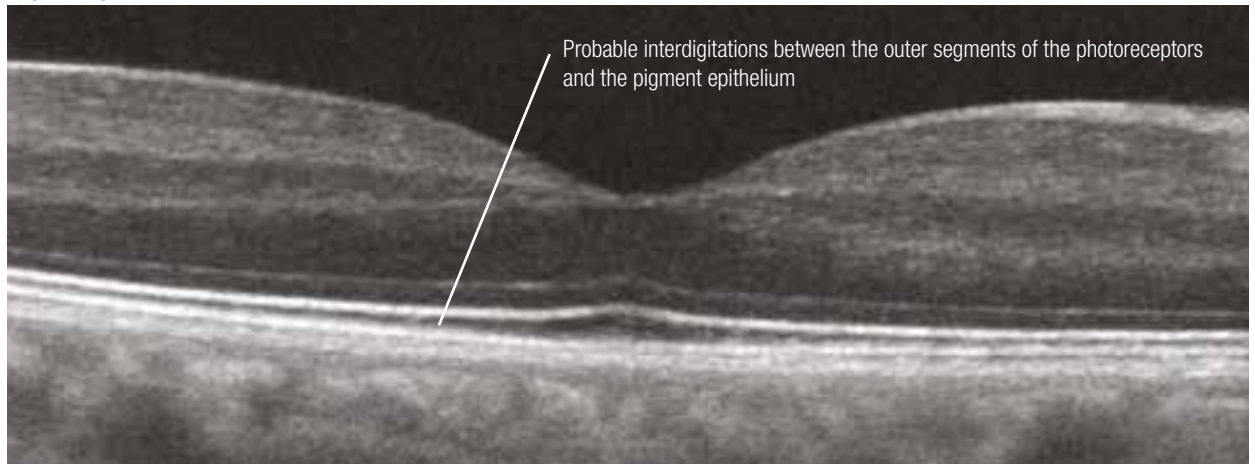
Regarding the outer retina, it is recognised that the most hyperreflective line corresponds to the junction between the inner and outer segments of the photoreceptors (also called the "photoreceptor integrity line"). The weakly reflective line located just above is the external limiting membrane. The outermost and thickest hyperreflective layer corresponds to the pigment epithelium-Bruch's membrane-choriocapillaris complex. In some cases, if the image quality is good, just below the junction between the inner and outer segments of the photoreceptors, it is possible to see interdigitations between the outer segments of the photoreceptors and the apical villi of the retinal pigment epithelium.

In enhanced depth imaging (EDI) mode, the most posterior layers are more visible and the Haller's layer (corresponding to large choroidal vessels) and the Sattler's layer (corresponding to medium-sized vessels) can be distinguished. The choroidoscleral boundary is also visible (blue arrows).

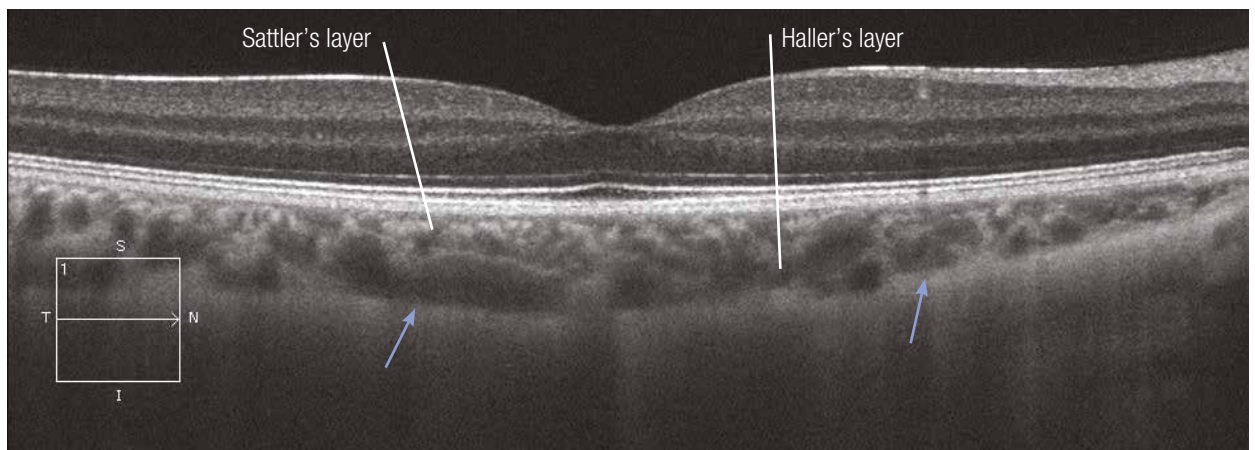
Normal OCT



High-magnification OCT



Normal OCT in EDI mode



2. Diseases of the vitreoretinal interface

- 2.1. Vitreomacular traction**
- 2.2. Macular hole**
- 2.3. Lamellar hole**
- 2.4. Epimacular membrane**

Vitreomacular traction syndrome

Case 1

The colour image is often poorly contributive to explain the patient's metamorphopsia. On the OCT image, the posterior hyaloid remains attached to the macular region where it appears hyperreflective. The adjacent fovea is elevated and microcystic. The "en-face" OCT section reveals the petaloid appearance of the retinal cysts.

Case 2

The posterior hyaloid adjacent to the macular region is greatly thickened and hyperreflective. The vitreomacular traction is even more pronounced with a marked elevation of the central vitreomacular adhesion zone. The outer retinal layer is intact.